


MODERN
RADIOLOGY
eBook

Breast Imaging

ESR EUROPEAN SOCIETY
OF RADIOLOGY



/ Preface

Modern Radiology is a free educational resource for radiology published online by the European Society of Radiology (ESR). The title of this second, rebranded version reflects the novel didactic concept of the *ESR eBook* with its unique blend of text, images, and schematics in the form of succinct pages, supplemented by clinical imaging cases, Q&A sections and hyperlinks allowing to switch quickly between the different sections of organ-based and more technical chapters, summaries and references.

Its chapters are based on the contributions of over 100 recognised European experts, referring to both general technical and organ-based clinical imaging topics. The new graphical look showing Asklepios with fashionable glasses, symbolises the combination of classical medical teaching with contemporary style education.

Although the initial version of the *ESR eBook* was created to provide basic knowledge for medical students and teachers of undergraduate courses, it has gradually expanded its scope to include more advanced knowledge for readers who wish to 'dig deeper'. As a result, *Modern*

Radiology covers also topics of the postgraduate levels of the *European Training Curriculum for Radiology*, thus addressing postgraduate educational needs of residents. In addition, it reflects feedback from medical professionals worldwide who wish to update their knowledge in specific areas of medical imaging and who have already appreciated the depth and clarity of the *ESR eBook* across the basic and more advanced educational levels.

I would like to express my heartfelt thanks to all authors who contributed their time and expertise to this voluntary, non-profit endeavour as well as Carlo Catalano, Andrea Laghi and András Palkó, who had the initial idea to create an *ESR eBook*, and - finally - to the ESR Office for their technical and administrative support.

Modern Radiology embodies a collaborative spirit and unwavering commitment to this fascinating medical discipline which is indispensable for modern patient care. I hope that this *educational* tool may encourage curiosity and critical thinking, contributing to the appreciation of the art and science of radiology across Europe and beyond.

Minerva Becker, Editor

Professor of Radiology, University of Geneva, Switzerland

/ Breast Imaging

CHAPTER OUTLINE:

- Breast Anatomy
- Anatomical Variants
- Pregnancy and Lactation
- Diagnostic Imaging Techniques
- Disease of the Breast: Benign
- Disease of the Breast: Malignant
- Axilla
- Interventional Procedures
- Screening
- High Risk Women
- Communication
- Multidisciplinary Team Meeting
- Take-Home Messages
- References
- Test Your Knowledge

/ Copyright and Terms of Use

This work is licensed under a [Creative Commons Attribution-NonCommercial-NoDerivatives 4.0 International License](https://creativecommons.org/licenses/by-nc-nd/4.0/).

You are free to:

Share, copy and redistribute the material in any medium or format

Under the following terms:

/ **ATTRIBUTION** – You must give appropriate credit, provide a link to the license, and **indicate if changes were made**. You may do so in any reasonable manner, but not in any way that suggests the licensor endorses you or your use.

/ **NONCOMMERCIAL** – You may not use the material for commercial purposes.

/ **NODERIVATIVES** – If you remix, transform, or build upon the material, you may not distribute the modified material.

How to cite this work:

European Society of Radiology,
Federica Pediconi, Fiona J. Gilbert, Francesca Galati,
Filipe Barros Alves, Pascal A.T. Baltzer, Melis Baykara
Ulusan, Paola Clauser, Francesca Ferrara, Elisabetta
Giannotti, Fleur Kilburn-Toppin, Maria Adele Marino,
Jessica Muscat, Simone Schiaffino, Rubina Manuela
Trimboli, Chantal Van Ongeval, Thiemo J.A. van Nijnat-
ten, Giulia Vatteroni, Mirjam Wielema (2025)
ESR Modern Radiology eBook:

/ **Breast Imaging.**
DOI 10.26044/esr-modern-radiology-11

/ Breast Imaging

CHAPTER OUTLINE:

Breast Anatomy
Anatomical Variants
Pregnancy and Lactation
Diagnostic Imaging Techniques
Disease of the Breast: Benign
Disease of the Breast: Malignant
Axilla
Interventional Procedures
Screening
High Risk Women
Communication
Multidisciplinary Team Meeting
Take-Home Messages
References
Test Your Knowledge

/ Signage

 **CORE KNOWLEDGE**

 **ATTENTION**

 **HYPERLINKS**

 **FURTHER KNOWLEDGE**

 **COMPARE**

 **REFERENCES**

 **QUESTIONS**

/ Breast Imaging

CHAPTER OUTLINE:

Breast Anatomy
 Anatomical Variants
 Pregnancy and Lactation
 Diagnostic Imaging Techniques
 Disease of the Breast: Benign
 Disease of the Breast: Malignant
 Axilla
 Interventional Procedures
 Screening
 High Risk Women
 Communication
 Multidisciplinary Team Meeting
 Take-Home Messages
 References
 Test Your Knowledge

Breast Imaging

EDITORS

Federica Pediconi | Fiona J. Gilbert

ASSISTANT EDITOR

Francesca Galati

AUTHORS

Filipe Barros Alves | Pascal A.T. Baltzer | Melis Baykara Ulasan | Paola Clauser | Francesca Ferrara
Francesca Galati | Elisabetta Giannotti | Fiona J. Gilbert | Fleur Kilburn-Toppin | Maria Adele Marino
Jessica Muscat | Federica Pediconi | Simone Schiaffino | Rubina Manuela Trimboli
Chantal Van Ongeval | Thiemo J.A. van Nijnatten | Giulia Vatteroni | Mirjam Wielema

AFFILIATION

European Society of Breast Imaging (EUSOBI)

CHAPTER OUTLINE:

Breast Anatomy
Anatomical Variants
Pregnancy and Lactation
Diagnostic Imaging
Techniques
Disease of the Breast:
Benign
Disease of the Breast:
Malignant
Axilla
Interventional Procedures
Screening
High Risk Women
Communication
Multidisciplinary Team
Meeting
Take-Home Messages
References
Test Your Knowledge

<↑> **HYPERLINK**

office@eusobi.org

Chapter Outline

Breast Anatomy

- / Introduction
- / Nipple-areola Complex
- / Breast Density
- / Quadrant Anatomy
- / Structure: Lobes and Lobules
- / Breast Anatomy During Pregnancy and Lactation
- / Male breast: Anatomy and Gynaecomastia

Anatomical Variants

- / Normal Variations In Development
- / Gynecomastia
- / Congenital and Development Abnormalities

Pregnancy and Lactation

- / Pregnancy
- / Partum
- / Lactation

Diagnostic Imaging Techniques

- / Mammography
- / DBT
- / US
- / MRI
- / CEM

Diseases of the Breast: Benign

- / Cysts
- / Fibrocystic Change
- / Fibroadenoma
- / Phylloides Tumour
- / Hamartoma
- / Lipoma and Angiolipoma
- / Mastitis/Abscess
- / Hematoma
- / Fat Necrosis

Disease of the Breast: Malignant

- / Imaging and Diagnostic Techniques
- / Histology of in Situ & Invasive Breast Cancer

Axilla

- / Anatomy
- / Appearance on Ultrasound
- / Intervention

Interventional Procedures

- / Fine-Needle Aspiration Cytology (FNAC)
- / Core Needle Biopsy (CNB)
- / Vacuum Assisted Biopsy (VAB)
- / Vacuum Assisted Excision (VAE)
- / Pre-Operative Localisation
- / Minimal Invasive Therapy

Communication

- / Mammography – Indications and Recommendations
- / Ultrasound – Indications
- / Triple Assessment
- / Breast Imaging Scenarios
- / Basic Considerations in Communicating with Patients

Multidisciplinary Team Meeting

- / Considerations in Communicating with Health Professionals
- / Multidisciplinary Team Meeting

Take-Home Messages

References

Test Your Knowledge

Breast Imaging

CHAPTER OUTLINE:

- Breast Anatomy
- Anatomical Variants
- Pregnancy and Lactation
- Diagnostic Imaging Techniques
- Disease of the Breast: Benign
- Disease of the Breast: Malignant
- Axilla
- Interventional Procedures
- Screening
- High Risk Women
- Communication
- Multidisciplinary Team Meeting
- Take-Home Messages
- References
- Test Your Knowledge

/ Breast Imaging

CHAPTER OUTLINE:

Breast Anatomy

Anatomical Variants

Pregnancy and Lactation

Diagnostic Imaging
Techniques

Disease of the Breast:
Benign

Disease of the Breast:
Malignant

Axilla

Interventional Procedures

Screening

High Risk Women

Communication

Multidisciplinary Team
Meeting

Take-Home Messages

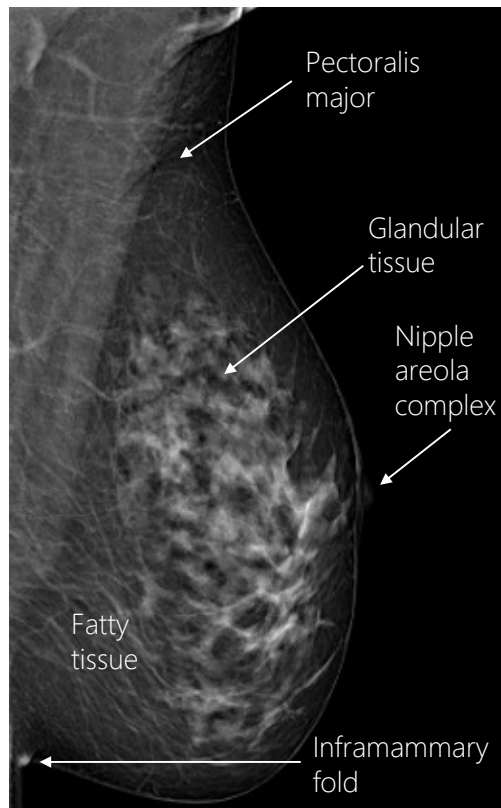
References

Test Your Knowledge

/ Breast Anatomy

/ Introduction

- / Female breasts are skin annexes, equal and symmetrical, with breastfeeding as their main function.
- / The breast is covered with skin, and at the apex it has a rounded pigmented area, the areola, in the center of which the nipple protrudes, resulting in the nipple areola complex (NAC).
- / Until puberty, the appearance and volume of the breasts are similar in both sexes. In women, when the breast develops, there can be notable variation in volume. Breast volume and texture are under the influence of genetic and endocrine stimuli. After puberty, in the male, the glandular part does not develop and, therefore, the breasts remain structurally in the prepubertal state for lifetime. In the female, at puberty, the breasts develop, with growth occurring by proliferation of all the components of the organ (parenchymal tissue, periductal stroma and interstitial connective tissue).



/ Breast Imaging

CHAPTER OUTLINE:

Breast Anatomy

/ Introduction

Anatomical Variants

Pregnancy and Lactation

Diagnostic Imaging Techniques

Disease of the Breast: Benign

Disease of the Breast: Malignant

Axilla

Interventional Procedures

Screening

High Risk Women

Communication

Multidisciplinary Team Meeting

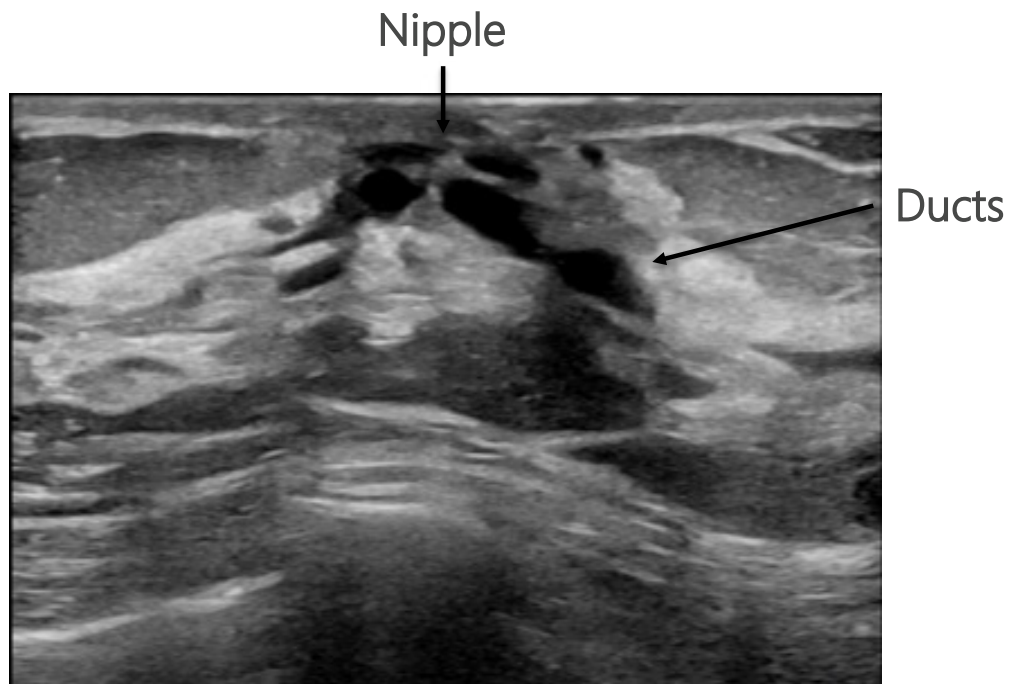
Take-Home Messages

References

Test Your Knowledge

/ Nipple-Areola Complex

Ultrasound (US) anatomy of the confluence of the ducts in the nipple areola complex in a normal breast. The ducts are identifiable as anechoic tubular structures that are oriented towards the nipple.



/ Breast Imaging

CHAPTER OUTLINE:

Breast Anatomy

/ Nipple-Areola Complex

Anatomical Variants

Pregnancy and Lactation

Diagnostic Imaging
Techniques

Disease of the Breast:
Benign

Disease of the Breast:
Malignant

Axilla

Interventional Procedures

Screening

High Risk Women

Communication

Multidisciplinary Team
Meeting

Take-Home Messages

References

Test Your Knowledge

/ Breast Density

Breast density is due to fibroglandular tissue. This varies during the menstrual cycle due to proliferation of the epithelial cells and increased vascularity.

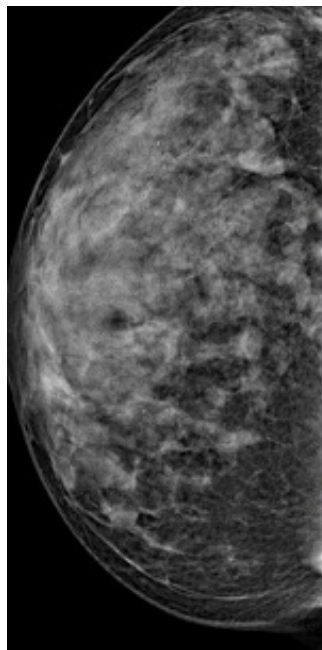
There is an increase in volume in pregnancy due to the development of the alveoli and related ducts.

At menopause, the glandular component of the breasts undergoes atrophy, while the connective support structures tend to relax. Hormone replacement therapy can increase breast density or prevent involution of breast glandular tissue.

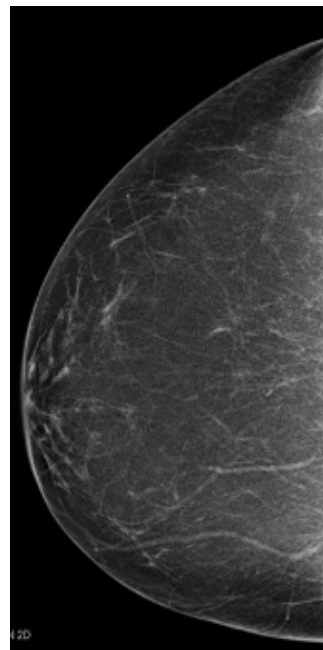
<=> ATTENTION

The quantity of glandular and connective components is classified on mammography by the ACR BI-RADS¹ into 4 categories:

- a: almost entirely fatty
- b: scattered areas of fibroglandular density
- c: heterogeneously dense
- d: extremely dense



Extremely dense



Almost entirely fatty

/ Breast Imaging

CHAPTER OUTLINE:

Breast Anatomy

/ Breast Density

Anatomical Variants

Pregnancy and Lactation

Diagnostic Imaging Techniques

Disease of the Breast: Benign

Disease of the Breast: Malignant

Axilla

Interventional Procedures

Screening

High Risk Women

Communication

Multidisciplinary Team Meeting

Take-Home Messages

References

Test Your Knowledge

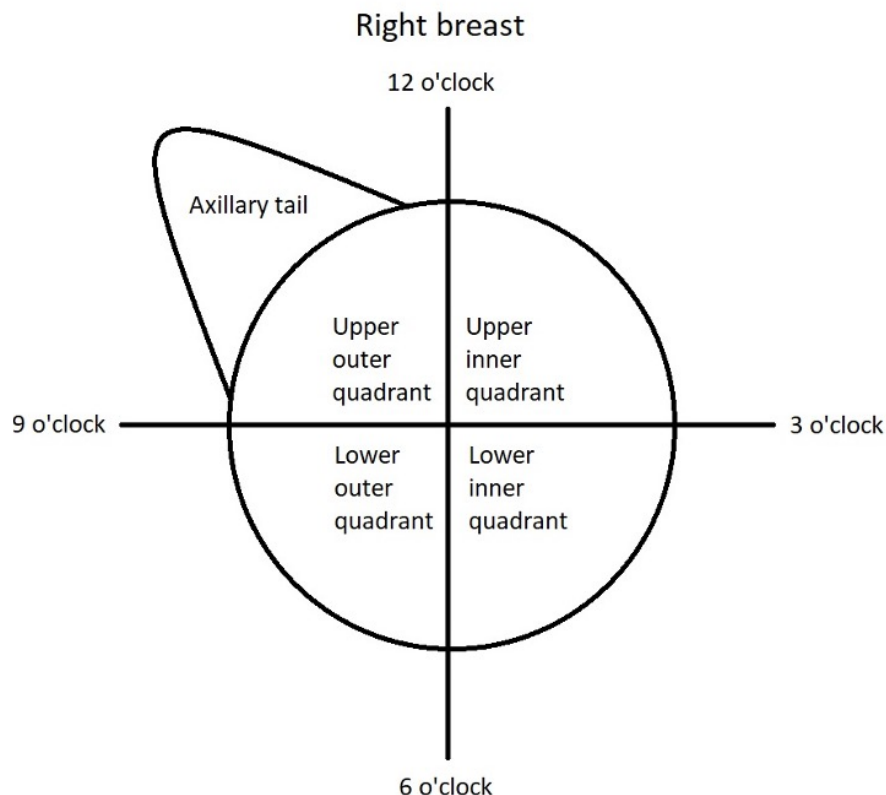
/ Quadrant Anatomy

Two perpendicular axes passing through the nipple divide the breast into four quadrants.

The axillary tail is added adjacent to the upper-external quadrant. Furthermore, the hours of the clock can be used to locate any focal lesion, adding the distance to the nipple, as shown in the figure.

<=> ATTENTION

The upper-outer quadrant is the one with the largest amount of glandular tissue and, therefore, is more frequent site of breast cancer.



CHAPTER OUTLINE:

Breast Anatomy

/ Breast Density

Anatomical Variants

Pregnancy and Lactation

Diagnostic Imaging Techniques

Disease of the Breast: Benign

Disease of the Breast: Malignant

Axilla

Interventional Procedures

Screening

High Risk Women

Communication

Multidisciplinary Team Meeting

Take-Home Messages

References

Test Your Knowledge

/ Structure: Lobes and Lobules

The breast contains glandular, fatty and connective tissue.

The glandular tissue (a modified apocrine gland) is divided in lobules, and produces the milk, which is drained by the mammary ducts to the nipple. The nipple areola complex (NAC) is part of the visible breast.

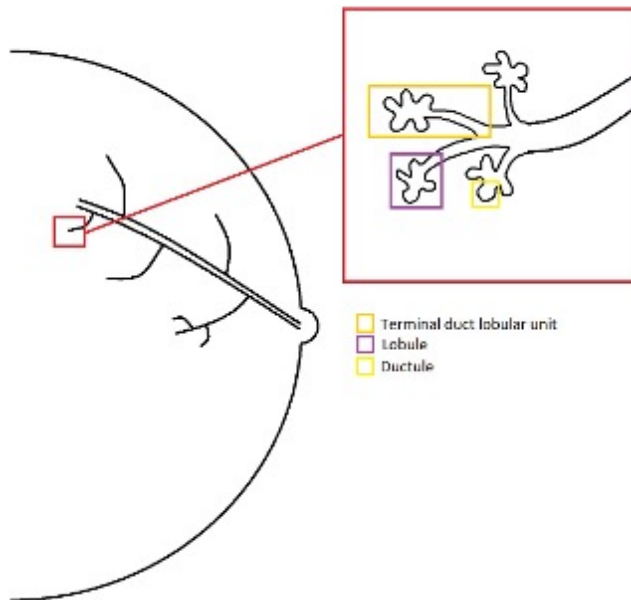
Connective bundles (retinacles) divide the glandular tissue into lobes and lobules.

Each breast has 12-20 lobes drained by a separate main duct per lobe.

<=> ATTENTION

TDLUs are epithelial structures that produces milk during lactation and are the main source of breast neoplasms precursors and cancers.

Each lobe includes several lobules of glandular tissue, also referred as terminal ductal lobular units (TDLU) and mammary ducts carrying milk from lobules to the nipple.



/ Breast Imaging

CHAPTER OUTLINE:

Breast Anatomy

/ Structure: Lobes and Lobules

Anatomical Variants

Pregnancy and Lactation

Diagnostic Imaging Techniques

Disease of the Breast: Benign

Disease of the Breast: Malignant

Axilla

Interventional Procedures

Screening

High Risk Women

Communication

Multidisciplinary Team Meeting

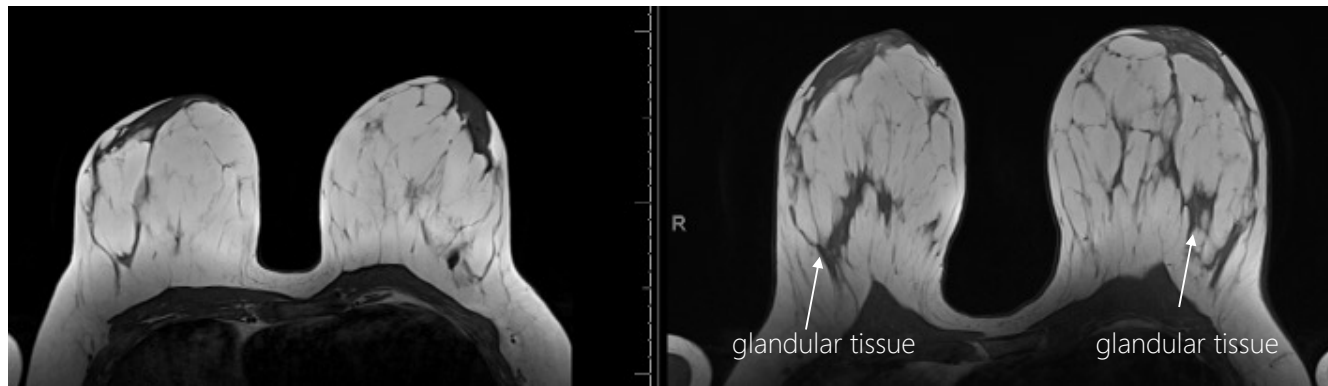
Take-Home Messages

References

Test Your Knowledge

/ Breast Anatomy During Pregnancy and Lactation

During the second month of gestation, the breasts grow due to lobular enlargement of the TDLUs and new TDLUs are formed. During the 3rd and 4th month of gestation the lobular glands distend even more, due to accumulation of secretions. Early lactation is accompanied by a further increase in the volume of the breasts, especially in the glandular component.



T1-weighted sequences before and during pregnancy in the same patient. There is an evident increase in volume and in the glandular tissue bilaterally.

/ Breast Imaging

CHAPTER OUTLINE:

Breast Anatomy

/ Breast Anatomy During Pregnancy and Lactation

Anatomical Variants

Pregnancy and Lactation

Diagnostic Imaging Techniques

Disease of the Breast: Benign

Disease of the Breast: Malignant

Axilla

Interventional Procedures

Screening

High Risk Women

Communication

Multidisciplinary Team Meeting

Take-Home Messages

References

Test Your Knowledge

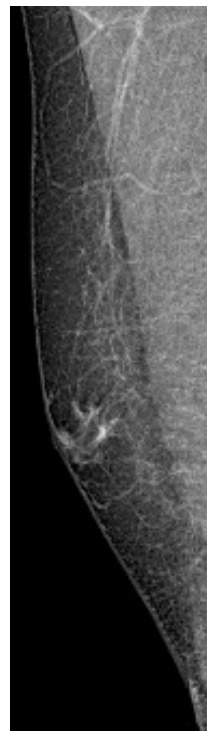
/ Male Breast: Anatomy and Gynaecomastia

In the male, the breast appear as a small, even and symmetrically located on the mid-clavicular line, at the level of the 4th intercostal space.

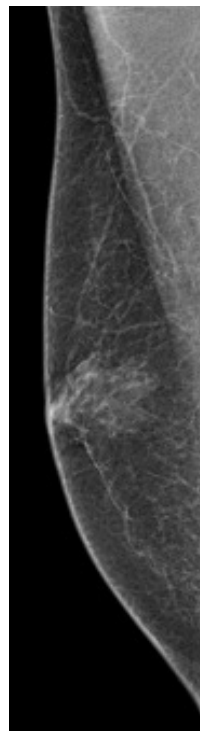
Structurally, the male breast is comparable to the female one before puberty. The glandular body is atrophic, in which the connective stromal tissue is dominant over the epithelial parenchyma.

At puberty, the male breast can undergo a temporary hypertrophy (**gynecomastia**), mostly unilateral, due to transient hormonal imbalance, with a prevalence of estrogen over androgens.

At older age gynaecomastia can develop due to the use of several drugs.



Normal male breast



Gynecomastia

/ Breast Imaging

CHAPTER OUTLINE:

Breast Anatomy

/ Male Breast: Anatomy and Gynaecomastia

Anatomical Variants

Pregnancy and Lactation

Diagnostic Imaging Techniques

Disease of the Breast: Benign

Disease of the Breast: Malignant

Axilla

Interventional Procedures

Screening

High Risk Women

Communication

Multidisciplinary Team Meeting

Take-Home Messages

References

Test Your Knowledge

CHAPTER OUTLINE:

Breast Anatomy

Anatomical Variants

Pregnancy and Lactation

Diagnostic Imaging
Techniques

Disease of the Breast:
Benign

Disease of the Breast:
Malignant

Axilla

Interventional Procedures

Screening

High Risk Women

Communication

Multidisciplinary Team
Meeting

Take-Home Messages

References

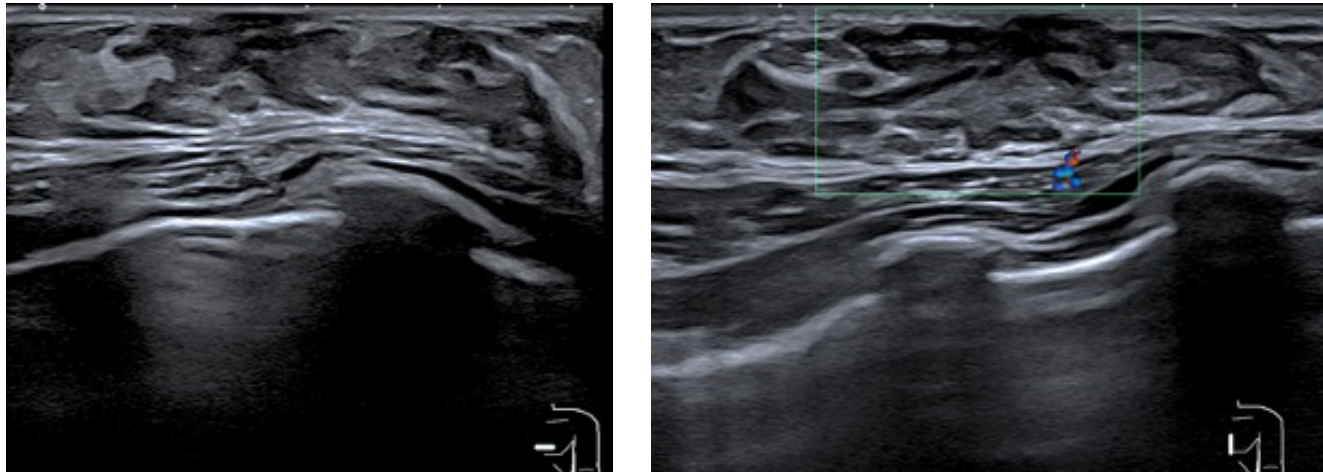
Test Your Knowledge

/ Anatomical Variants

/ Normal Variations in Development

Premature thelarche: breast development < 7½ years, unilateral/bilateral, normal breast tissue on Ultrasound (US):

Idiopathic premature thelarche: 1-3 years old unusual after 4 years, self-limited.



Ultrasound of 3 years old girl in presence of palpable lump behind left nipple shows breast bud/ normal breast tissue in keeping with premature thelarche

/ Breast Imaging

CHAPTER OUTLINE:

Breast Anatomy

Anatomical Variants

/ Normal Variations in Development

Pregnancy and Lactation

Diagnostic Imaging Techniques

Disease of the Breast: Benign

Disease of the Breast: Malignant

Axilla

Interventional Procedures

Screening

High Risk Women

Communication

Multidisciplinary Team Meeting

Take-Home Messages

References

Test Your Knowledge

/ Gynecomastia

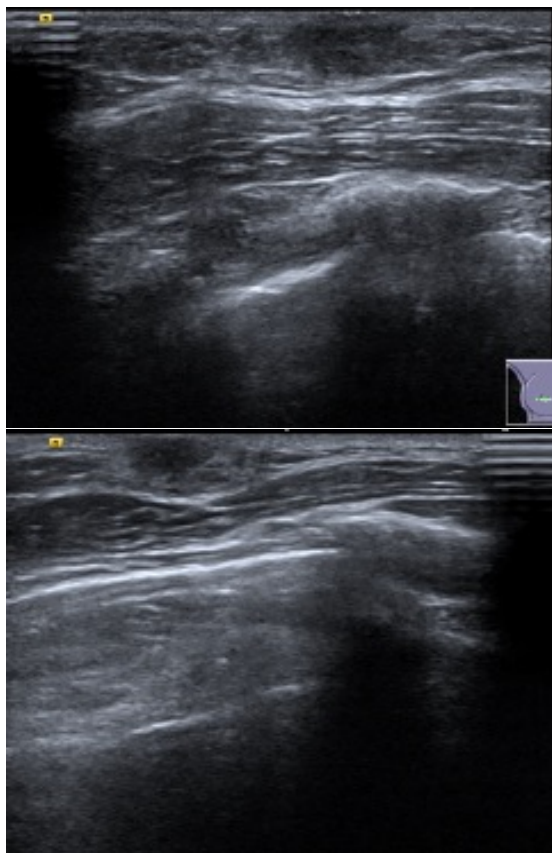
> excessive development of the breast tissue in male:

Physiologic:

- / In 90% of neonates transient breast hypertrophy due to maternal hormone
- / 1 year after puberty and for 1-2 years (75% healthy boys)

Further causes:

- / Anabolic steroids, digitalis, isoniazid, tricyclic antidepressants, marijuana
- / General obesity: pseudo gynecomastia
- / Klinefelter syndrome, anorchism, acquired testicular failure androgen receptor defects



Ultrasound shows typical US appearance of gynecomastia

/ Breast Imaging

CHAPTER OUTLINE:

Breast Anatomy

Anatomical Variants

/ Gynecomastia

Pregnancy and Lactation

Diagnostic Imaging Techniques

Disease of the Breast: Benign

Disease of the Breast: Malignant

Axilla

Interventional Procedures

Screening

High Risk Women

Communication

Multidisciplinary Team Meeting

Take-Home Messages

References

Test Your Knowledge

/ Congenital and Developmental Abnormalities

Anomalous nipple and breast development:

- / **Polythelia** > accessory nipples, most common
- / **Polymastia** > accessory tissue incomplete involution of mammary ridge, usually enlarged during pregnancy and lactation
- / **Amastia** > absence of breast development
- / **Hyperplasia and Hypoplasia** > unilateral or bilateral
- / **Congenital inversion of nipple** (3%) associated with duct ectasia, periductal mastitis
- / **Ectopic breast tissue:** along the mammary ridge or milk line. Incomplete involution of ectodermal mammary ridge. Most common in the axilla (2-6% women)
- / **Poland syndrome** > child born with missing or underdeveloped pectoralis muscle, breast hypoplasia or aplasia, rib and chest wall deformities, and ipsilateral limb abnormalities [rare 1/36.000-50.000]

/ Breast Imaging

CHAPTER OUTLINE:

Breast Anatomy

Anatomical Variants

/ Congenital and Developmental Abnormalities

Pregnancy and Lactation

Diagnostic Imaging Techniques

Disease of the Breast: Benign

Disease of the Breast: Malignant

Axilla

Interventional Procedures

Screening

High Risk Women

Communication

Multidisciplinary Team Meeting

Take-Home Messages

References

Test Your Knowledge

Breast Imaging

CHAPTER OUTLINE:

Breast Anatomy

Anatomical Variants

/ Congenital and Developmental Abnormalities

Pregnancy and Lactation

Diagnostic Imaging Techniques

Disease of the Breast: Benign

Disease of the Breast: Malignant

Axilla

Interventional Procedures

Screening

High Risk Women

Communication

Multidisciplinary Team Meeting

Take-Home Messages

References

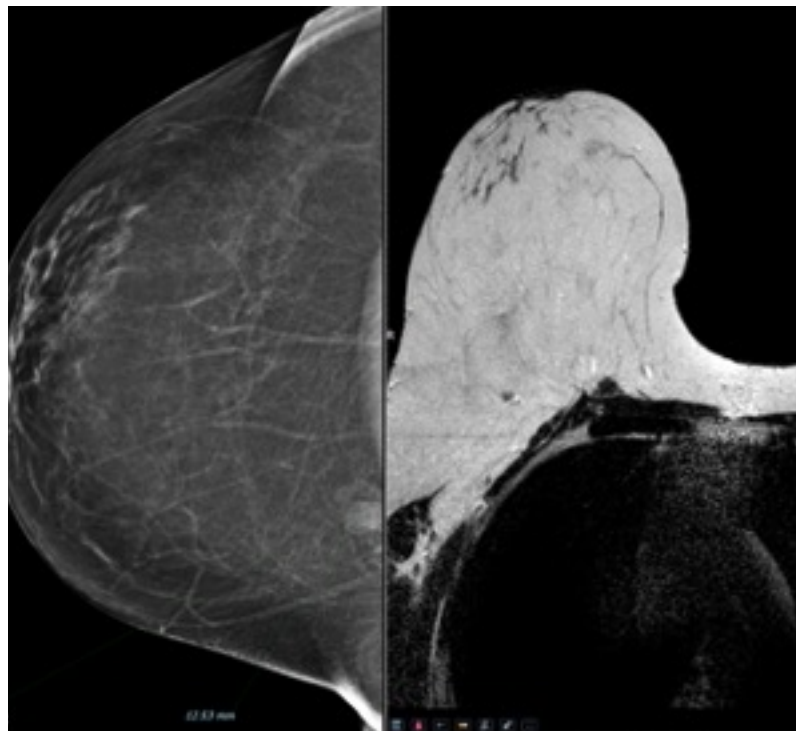
Test Your Knowledge

Sternalis muscle:

/ Uncommon anatomic variant of the chest wall musculature.

<!> ATTENTION

/ Often cause of false positives in mammography.



Mammogram and MRI images of sternalis muscle

CHAPTER OUTLINE:

Breast Anatomy

Anatomical Variants

Pregnancy and Lactation

Diagnostic Imaging
Techniques

Disease of the Breast:
Benign

Disease of the Breast:
Malignant

Axilla

Interventional Procedures

Screening

High Risk Women

Communication

Multidisciplinary Team
Meeting

Take-Home Messages

References

Test Your Knowledge

/ Pregnancy and Lactation

/ Pregnancy

Physiological changes in the architecture of the breast to prepare for breast feeding (increased serum level of oestrogen, progesterone and prolactin):

- / **Marked ductal and lobular proliferation in early weeks of pregnancy**
- / **Weeks 5-9** generalised breast enlargement and progressive increase in nipple-areolar complex pigmentation
- / **First trimester** under the influence of oestrogen, ductal proliferation and growth, alveolar-lobular growth. Expansion of the glandular tissue results in invasion of adipose tissue, which progresses gradually, occurring simultaneous to increased vascularity and blood flow
- / **Second half of pregnancy** hyperplasia, as well as the continuous involution of the fibrofatty stroma, colostrum accumulates in alveoli

<=> ATTENTION

As a result of these changes, the typical image of the breast at ultrasonography (US) is diffusely hypoechoic during pregnancy due to the increase in glandular tissue.

/ Breast Imaging

CHAPTER OUTLINE:

Breast Anatomy

Anatomical Variants

Pregnancy and Lactation

/ Pregnancy

Diagnostic Imaging Techniques

Disease of the Breast: Benign

Disease of the Breast: Malignant

Axilla

Interventional Procedures

Screening

High Risk Women

Communication

Multidisciplinary Team Meeting

Take-Home Messages

References

Test Your Knowledge

/ Partum

/ Post Partum

/ At the end of the pregnancy high levels of oestrogens and progesterone counteract prolactin, this inhibiting milk production, although colostrum production occurs in the alveolar cells.

/ **After delivery:** The reduction in oestrogen and progesterone levels results in the continuous release of prolactin, by hypothalamus, and the physical stimulation of the nipple by the new-born suction promotes the release of oxytocin by the anterior pituitary gland, in order to stimulate and maintain lactation.

/ Breast Imaging

CHAPTER OUTLINE:

Breast Anatomy

Anatomical Variants

Pregnancy and Lactation

/ Partum

Diagnostic Imaging
Techniques

Disease of the Breast:
Benign

Disease of the Breast:
Malignant

Axilla

Interventional Procedures

Screening

High Risk Women

Communication

Multidisciplinary Team
Meeting

Take-Home Messages

References

Test Your Knowledge

Breast Imaging

CHAPTER OUTLINE:

Breast Anatomy

Anatomical Variants

Pregnancy and Lactation

/ Partum

Diagnostic Imaging
Techniques

Disease of the Breast:
Benign

Disease of the Breast:
Malignant

Axilla

Interventional Procedures

Screening

High Risk Women

Communication

Multidisciplinary Team
Meeting

Take-Home Messages

References

Test Your Knowledge

Lactogenesis > Conversion from a proliferative state during pregnancy to a secretory state during lactation.

- / The amount of milk produced **does not** correlate with the amount of glandular tissue, the number of ducts, or the mean duct diameter
- / Immediate post-partum enlargement due to colostrum accumulation
- / **3-7 days post partum** milk secreted into alveoli
- / Post-lactational changes: periductal perivascular stromal connective tissue increases
- / Alveolar cells and ductal branches regress

<=> ATTENTION

As a result of these changes, in ultrasonography (US) the typical image of the breast becomes diffusely hyperechoic during lactation, as a function of increased vascularity and prominence of the ducts.

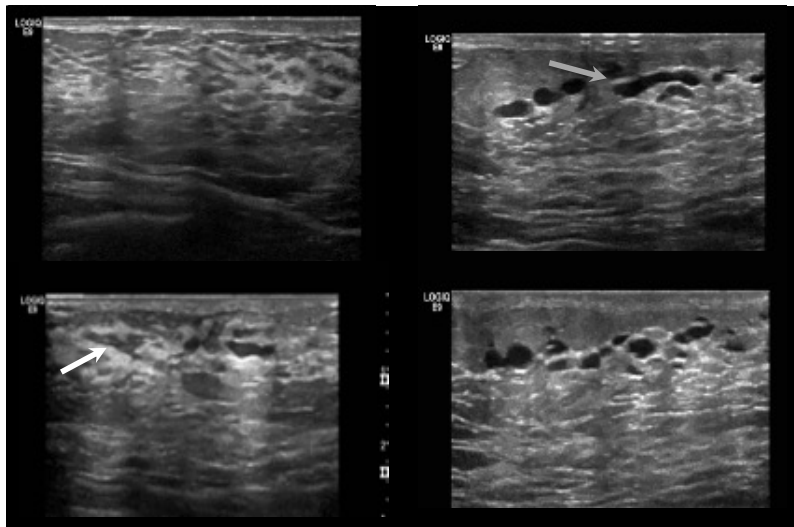
/ Lactation

Mammographic findings (for screening, wait 3 months after discontinuing lactation):

- / Diffuse increase in size and density
- / Little to no change to breast density

US Findings:

- / Increase in parenchymal echogenicity
- / Ductal ectasia
- / Increased vascularity



Ultrasound of breastfeeding woman. The B-mode US shows increased echogenicity pattern of the fibroglandular tissue, with bilateral dilated ducts (grey arrow). Some of them are filled with echogenic material (white arrow).

/ Breast Imaging

CHAPTER OUTLINE:

- Breast Anatomy
- Anatomical Variants
- Pregnancy and Lactation**
 - / Partum
- Diagnostic Imaging Techniques
- Disease of the Breast: Benign
- Disease of the Breast: Malignant
- Axilla
- Interventional Procedures
- Screening
- High Risk Women
- Communication
- Multidisciplinary Team Meeting
- Take-Home Messages
- References
- Test Your Knowledge

CHAPTER OUTLINE:

Breast Anatomy

Anatomical Variants

Pregnancy and Lactation

**Diagnostic Imaging
Techniques**

Disease of the Breast:
Benign

Disease of the Breast:
Malignant

Axilla

Interventional Procedures

Screening

High Risk Women

Communication

Multidisciplinary Team
Meeting

Take-Home Messages

References

Test Your Knowledge

/ Diagnostic Imaging Techniques

/ Diagnostic Imaging Techniques

The most important diagnostic imaging techniques used in breast radiology/imaging are:

- / Mammography
- / Digital Breast Tomosynthesis (DBT)
- / Ultrasound (US)
- / Magnetic Resonance Imaging (MRI)
- / Contrast-enhanced Mammography (CEM)

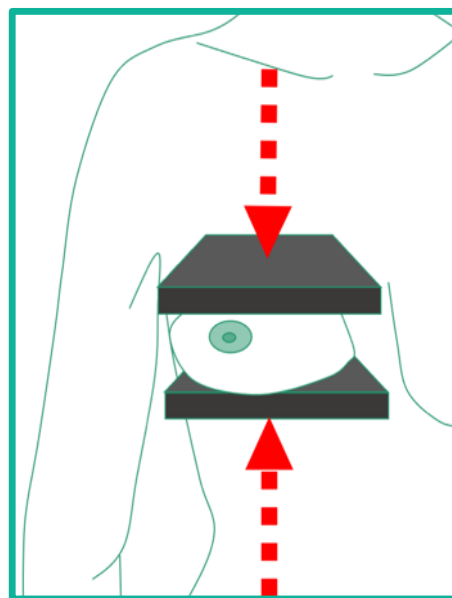
/ Breast Imaging

CHAPTER OUTLINE:

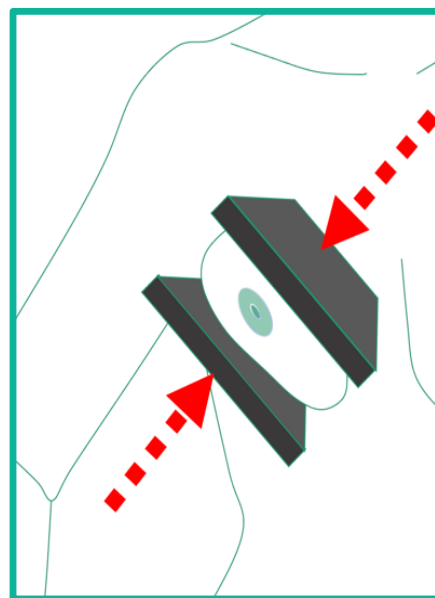
- Breast Anatomy
- Anatomical Variants
- Pregnancy and Lactation
- Diagnostic Imaging Techniques**
- Disease of the Breast: Benign
- Disease of the Breast: Malignant
- Axilla
- Interventional Procedures
- Screening
- High Risk Women
- Communication
- Multidisciplinary Team Meeting
- Take-Home Messages
- References
- Test Your Knowledge

/ Mammography

- / Mammography is a radiographic technique specifically designed for breast imaging
- / For the acquisition of **mammograms** – the images produced by mammography –, the breast is compressed in order to allow the dispersion of its components and facilitate their visualisation
- / The standard mammographic views are the **craniocaudal (CC)** and **mediolateral oblique (MLO)** views



CC view



MLO view

Orientation of the acquisition of the craniocaudal (CC) and mediolateral oblique (MLO) views.

/ Breast Imaging

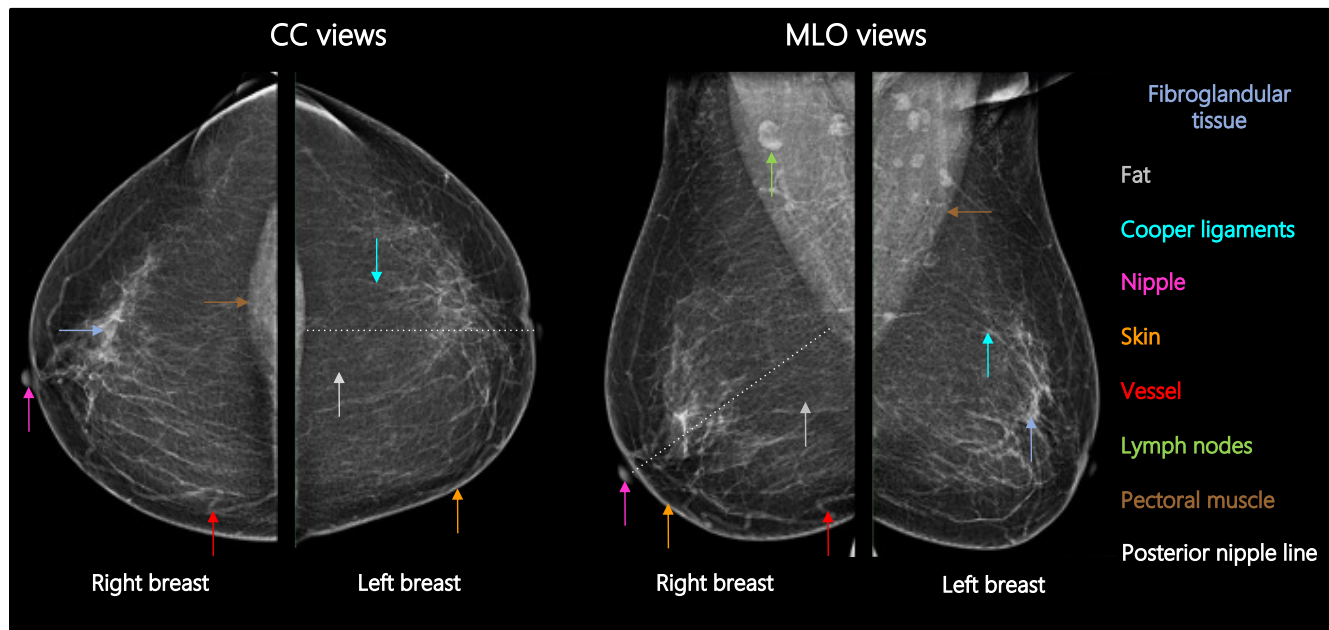
CHAPTER OUTLINE:

- Breast Anatomy
- Anatomical Variants
- Pregnancy and Lactation
- Diagnostic Imaging Techniques**
 - / Mammography
- Disease of the Breast: Benign
- Disease of the Breast: Malignant
- Axilla
- Interventional Procedures
- Screening
- High Risk Women
- Communication
- Multidisciplinary Team Meeting
- Take-Home Messages
- References
- Test Your Knowledge

/ Breast Imaging

CHAPTER OUTLINE:

- Breast Anatomy
- Anatomical Variants
- Pregnancy and Lactation
- Diagnostic Imaging Techniques**
 - / Mammography
- Disease of the Breast: Benign
- Disease of the Breast: Malignant
- Axilla
- Interventional Procedures
- Screening
- High Risk Women
- Communication
- Multidisciplinary Team Meeting
- Take-Home Messages
- References
- Test Your Knowledge



Breast anatomy as seen at normal mammography.

Principles

Quality criteria of adequate positioning for Mammography include:

CC views:

- / Well-visualised posterior medial breast
- / Pectoralis muscle should be demonstrated when possible
- / If the pectoralis muscle is not included, the length of the posterior nipple line (PNL) – an imaginary line extending posteriorly and perpendicularly from the nipple to the pectoralis muscle – on CC and MLO views should be within 1 cm of each other
- / Fat is seen posterior to the fibroglandular tissue
- / Nipple in profile

MLO views:

- / Pectoralis muscle extends inferior to the PNL
- / Convex anterior border of the pectoralis muscle
- / Pectoralis muscle is wider superiorly and narrows inferiorly
- / Open inframammary fold
- / Fat is seen posterior to the fibroglandular tissue
- / Nipple in profile

Breast Imaging

CHAPTER OUTLINE:

- Breast Anatomy
- Anatomical Variants
- Pregnancy and Lactation
- Diagnostic Imaging Techniques**
 - / Mammography
- Disease of the Breast: Benign
- Disease of the Breast: Malignant
- Axilla
- Interventional Procedures
- Screening
- High Risk Women
- Communication
- Multidisciplinary Team Meeting
- Take-Home Messages
- References
- Test Your Knowledge

/ Breast Imaging

CHAPTER OUTLINE:

Breast Anatomy
Anatomical Variants
Pregnancy and Lactation

Diagnostic Imaging Techniques

/ Mammography

Disease of the Breast:
Benign

Disease of the Breast:
Malignant

Axilla

Interventional Procedures

Screening

High Risk Women

Communication

Multidisciplinary Team Meeting

Take-Home Messages

References

Test Your Knowledge

- / The **Average Glandular Dose (AGD)** = estimate of the average absorbed dose by the glandular breast tissue during Mammography measured in Gray (Gy):

$$AGD = K \times g \times c \times s$$

K: entrant surface air kerma

g: conversion factor for 50% glandular breast based on thickness and half-value layer

c: correction factor based on non-standard glandularity/thickness

s: correction factor based on non-molybdenum anode/filter combination

- / AGD levels in Mammography are between 0,8 and 2,5 mGy for 4,5 cm PMMA (Polymethyl methacrylate) phantoms in clinical settings
- / AGD levels in Mammography increase with increased breast thickness
- / **Limiting AGD:** 3-4 mGy

/ Breast Imaging

CHAPTER OUTLINE:

Breast Anatomy

Anatomical Variants

Pregnancy and Lactation

Diagnostic Imaging Techniques

/ Mammography

Disease of the Breast:
Benign

Disease of the Breast:
Malignant

Axilla

Interventional Procedures

Screening

High Risk Women

Communication

Multidisciplinary Team
Meeting

Take-Home Messages

References

Test Your Knowledge

Main Indications

Screening Mammography:

- / Applied on asymptomatic women to identify breast cancer at an early/ potentially curable stage;
- / Starting from the age of 45-50 to the age of 70-74 depending on the country.

Diagnostic Mammography:

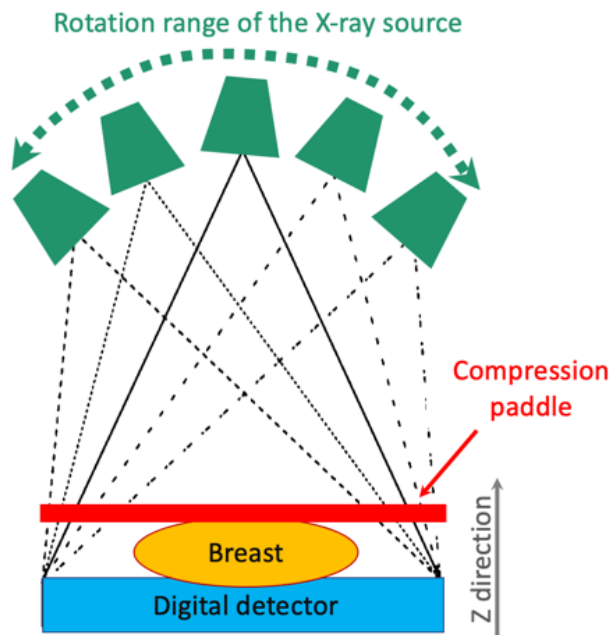
- / Applied on symptomatic patients or to work-up an abnormality found on Screening Mammography.
- / The standard mammographic views are supplemented with additional views (eg. lateral view, spot compression etc.) to further assess the screening-detected abnormality.

/ Digital Breast Tomosynthesis (DBT)

>|< COMPARE

Principles/Relative Diagnostic Value/Main Indications

- / DBT produces quasi-3D images of the breast, based on the reconstruction of several low-dose 2D-projections acquired in a limited range of x-ray tube angles.
- / It reduces the burden of overlapping tissues in the evaluation of standard mammography and improves the detection and the delineation of findings, increasing the sensitivity and the specificity/ decreasing the false negatives and the false positives
- / It is particularly useful in the detection and delineation of masses and architectural distortions and in the further evaluation of asymmetries.



The x-ray source rotates around the compressed breast within a limited range (green dashed line). Projection images are formed on the detector. These are then reconstructed through the breast volume along the Z direction.

/ Breast Imaging

CHAPTER OUTLINE:

Breast Anatomy
Anatomical Variants
Pregnancy and Lactation

Diagnostic Imaging Techniques

/ DBT

Disease of the Breast:
Benign

Disease of the Breast:
Malignant

Axilla

Interventional Procedures

Screening

High Risk Women

Communication

Multidisciplinary Team Meeting

Take-Home Messages

References

Test Your Knowledge

>|< COMPARE

Breast Imaging

CHAPTER OUTLINE:

Breast Anatomy
Anatomical Variants
Pregnancy and Lactation
Diagnostic Imaging Techniques
/ DBT
Disease of the Breast: Benign
Disease of the Breast: Malignant
Axilla
Interventional Procedures
Screening
High Risk Women
Communication
Multidisciplinary Team Meeting
Take-Home Messages
References
Test Your Knowledge

Principles/Relative Diagnostic Value

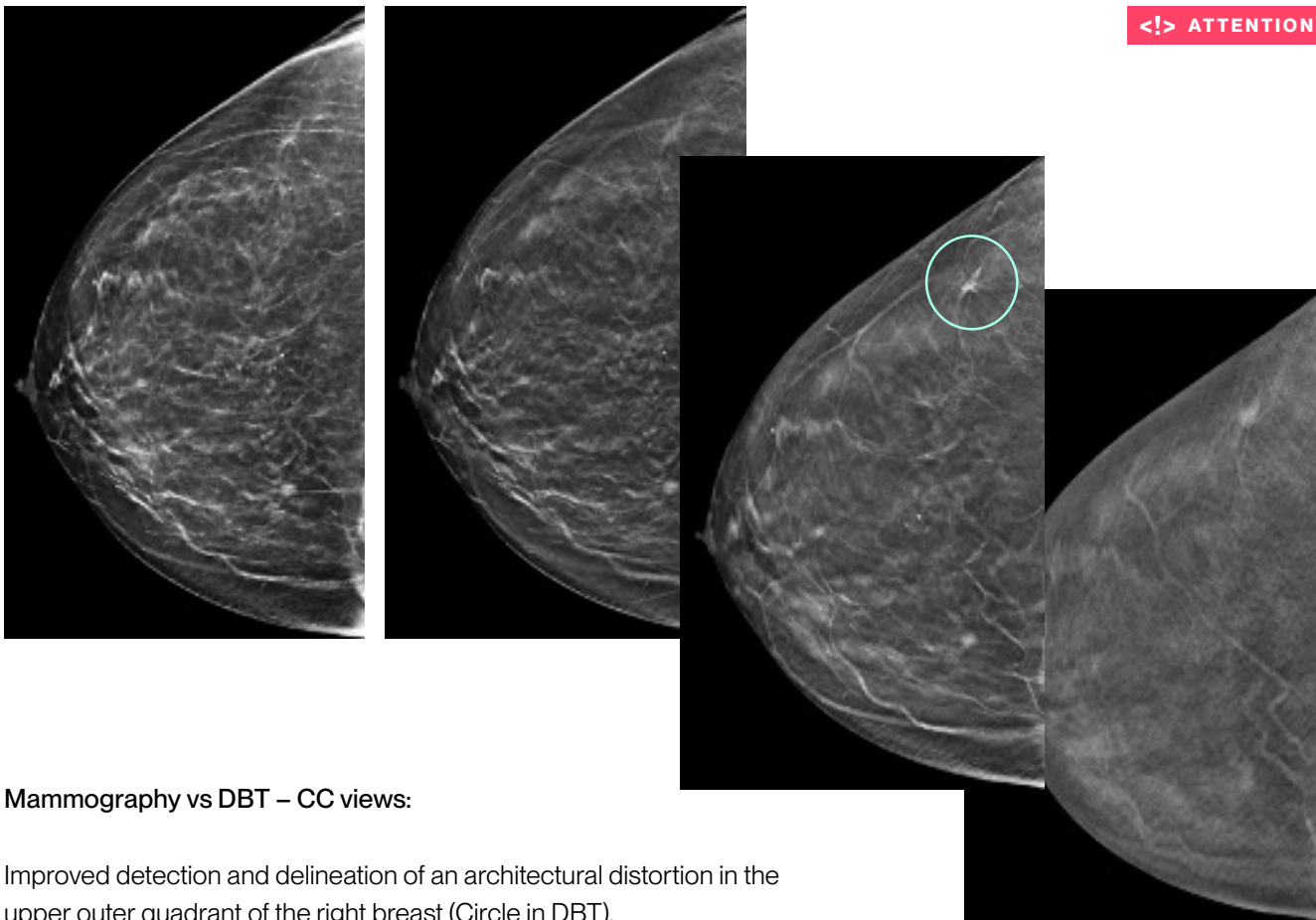
/ DBT allows the production of **synthetic mammograms** – images similar in appearance to Digital Mammography (DM) that are generated based on the data acquired with DBT, without the need to further expose the breasts to additional radiation.

/ The radiation dose from DBT alone is currently similar or only slightly higher to that of DM.

<!=> ATTENTION

DBT allows improved detection of architectural distortion in comparison to DM!

<=> ATTENTION



Mammography vs DBT – CC views:

Improved detection and delineation of an architectural distortion in the upper outer quadrant of the right breast (Circle in DBT).

Breast Imaging

CHAPTER OUTLINE:

- Breast Anatomy
- Anatomical Variants
- Pregnancy and Lactation
- Diagnostic Imaging Techniques**
 - / DBT
- Disease of the Breast: Benign
- Disease of the Breast: Malignant
- Axilla
- Interventional Procedures
- Screening
- High Risk Women
- Communication
- Multidisciplinary Team Meeting
- Take-Home Messages
- References
- Test Your Knowledge

>|< COMPARE

Breast Imaging

CHAPTER OUTLINE:

Breast Anatomy
Anatomical Variants
Pregnancy and Lactation
Diagnostic Imaging Techniques
/ DBT
Disease of the Breast: Benign
Disease of the Breast: Malignant
Axilla
Interventional Procedures
Screening
High Risk Women
Communication
Multidisciplinary Team Meeting
Take-Home Messages
References
Test Your Knowledge

Relative Diagnostic Value

Main disadvantages compared to Mammography

- / Longer evaluation time – approximately 2 times more
- / Artifacts:
 - / Blurring (continuous image acquisition)
 - / Motion (longer scanning time)

/ Breast Imaging

CHAPTER OUTLINE:

Breast Anatomy

Anatomical Variants

Pregnancy and Lactation

Diagnostic Imaging Techniques

/ DBT

Disease of the Breast:
Benign

Disease of the Breast:
Malignant

Axilla

Interventional Procedures

Screening

High Risk Women

Communication

Multidisciplinary Team
Meeting

Take-Home Messages

References

Test Your Knowledge

Principles

/ **Breast density** refers to the relative amount of fibroglandular tissue comparing to fat in the breast.

<!-- ATTENTION

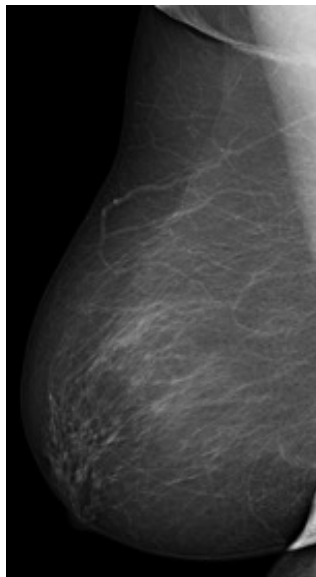
- / The 5th edition of **BI-RADS (Breast imaging-reporting and data system)** classifies breast density according to four **descriptors** (see also page 10):
 - / a: The breasts are almost entirely fatty;
 - / b: There are scattered areas of fibroglandular density;
 - / c: The breasts are heterogeneously dense, which may obscure small masses;
 - / d: The breasts are extremely dense, which lowers the sensitivity of Mammography.

>< COMPARE

Breast Imaging

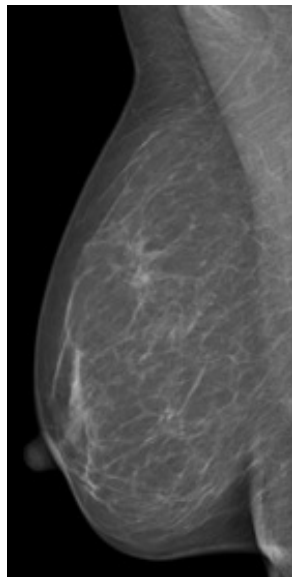
CHAPTER OUTLINE:

- Breast Anatomy
- Anatomical Variants
- Pregnancy and Lactation
- Diagnostic Imaging Techniques**
 - / DBT
- Disease of the Breast: Benign
- Disease of the Breast: Malignant
- Axilla
- Interventional Procedures
- Screening
- High Risk Women
- Communication
- Multidisciplinary Team Meeting
- Take-Home Messages
- References
- Test Your Knowledge



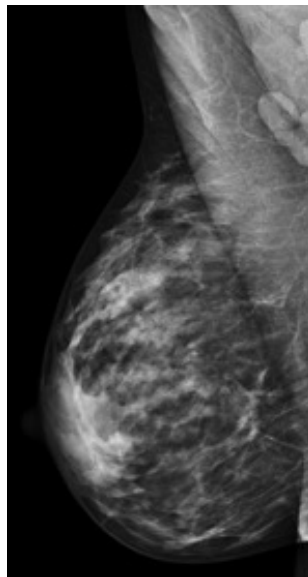
A

The breasts are almost entirely fatty



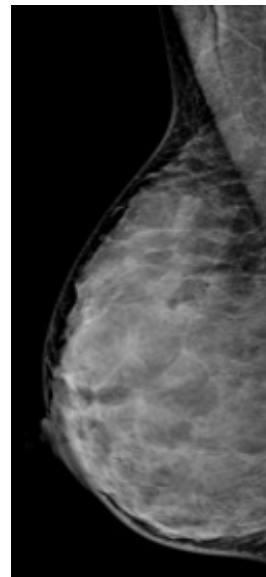
B

There are scattered areas of fibroglandular density



C

The breasts are heterogeneously dense, which may obscure small masses



D

The breasts are extremely dense, which lowers the sensitivity of Mammography

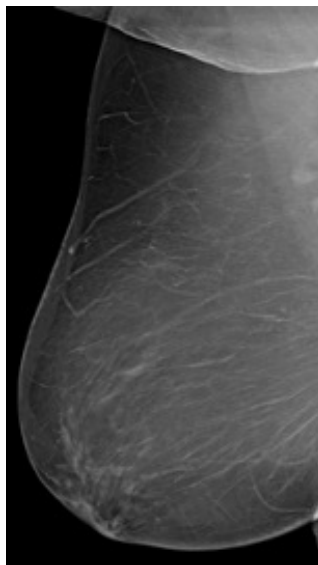
Breast density – Digital mammograms.

>< COMPARE

Breast Imaging

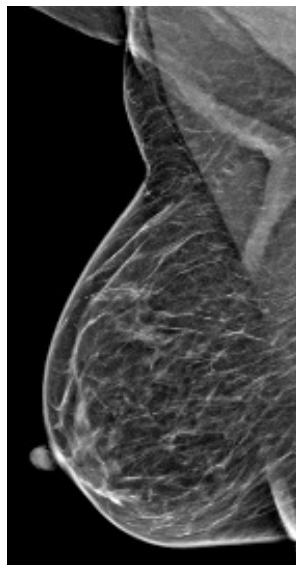
CHAPTER OUTLINE:

- Breast Anatomy
- Anatomical Variants
- Pregnancy and Lactation
- Diagnostic Imaging Techniques**
 - / DBT
- Disease of the Breast: Benign
- Disease of the Breast: Malignant
- Axilla
- Interventional Procedures
- Screening
- High Risk Women
- Communication
- Multidisciplinary Team Meeting
- Take-Home Messages
- References
- Test Your Knowledge



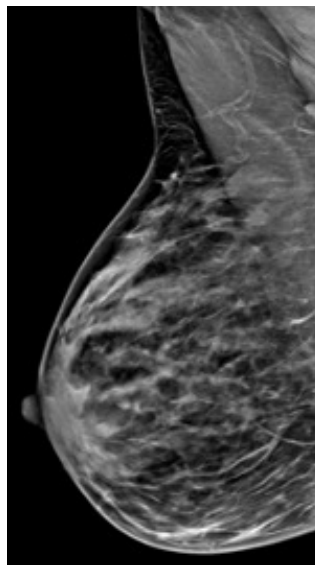
A

The breasts are almost entirely fatty



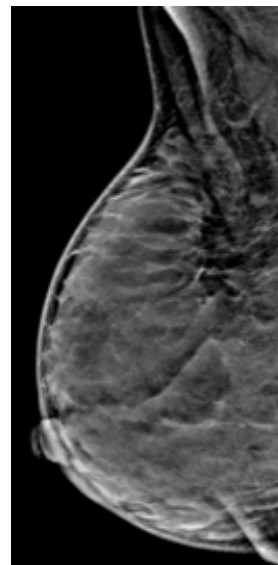
B

There are scattered areas of fibroglandular density



C

The breasts are heterogeneously dense, which may obscure small masses



D

The breasts are extremely dense, which lowers the sensitivity of Mammography

/ Ultrasound (US)

Breast US is an imaging technique that uses sound waves to visualise breast tissue:

- / The US transducer sends ultrasound pulses and receives echoes that contain spatial and contrast information regarding the tissues that are being scanned

>=< FURTHER KNOWLEDGE

- / It is recommended using high-frequency transducers, with a broad bandwidth operating at a centre frequency of at least 12 MHz and preferably higher

<!=> ATTENTION

- > See also eBook chapter on Ultrasound

/ Breast Imaging

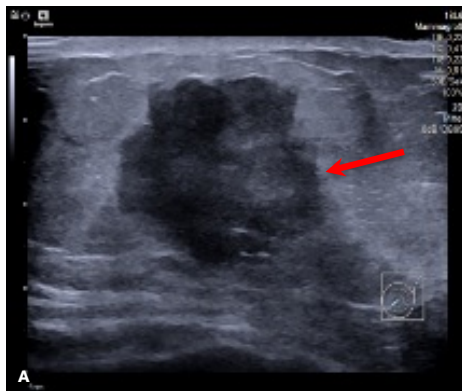CHAPTER OUTLINE:

- Breast Anatomy
- Anatomical Variants
- Pregnancy and Lactation
- Diagnostic Imaging Techniques**
 - / US
 - Disease of the Breast: Benign
 - Disease of the Breast: Malignant
 - Axilla
 - Interventional Procedures
 - Screening
 - High Risk Women
 - Communication
 - Multidisciplinary Team Meeting
 - Take-Home Messages
 - References
 - Test Your Knowledge

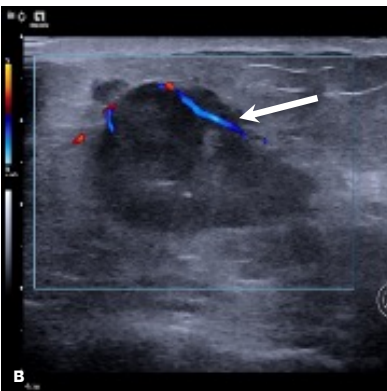
Breast US modalities include:

- / **B-mode (Grey-scale)** – the standard modality
- / **Doppler** – allows the evaluation of vascularisation (e.g., simple cysts – absent vascularity vs solid lesions – present vascularity)
- / **Elastography** – allows the evaluation of stiffness (benign tumours – tend to be softer vs. malignant tumours – tend to be harder)

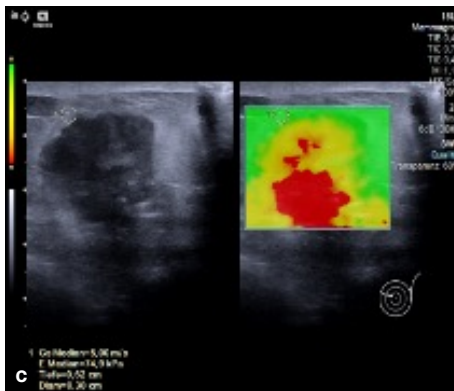B-mode



Doppler



Elastography



Breast US: B mode, Doppler and Elastography modalities revealing a biopsy-proven invasive breast cancer presenting as an irregular lesion (with microlobulated and angular margins, red arrow, A) heterogeneous hard mass exhibiting internal vascularity (white arrow, B) located in the inner quadrants of the left breast. Increased stiffness at elastography (C).

Breast Imaging

CHAPTER OUTLINE:

- Breast Anatomy
- Anatomical Variants
- Pregnancy and Lactation

Diagnostic Imaging Techniques

- / US

Disease of the Breast: Benign

Disease of the Breast: Malignant

Axilla

Interventional Procedures

Screening

High Risk Women

Communication

Multidisciplinary Team Meeting

Take-Home Messages

References

Test Your Knowledge

Relative Diagnostic Value

>|< COMPARE

MAIN ADVANTAGES:

- + Non-ionising radiation;
- + More available;
- + Less expensive.

MAIN DISADVANTAGES:

- "Operator dependence";
- Longer scanning time.

/ Breast Imaging

CHAPTER OUTLINE:

- Breast Anatomy
- Anatomical Variants
- Pregnancy and Lactation
- Diagnostic Imaging Techniques**
 - / US
- Disease of the Breast: Benign
- Disease of the Breast: Malignant
- Axilla
- Interventional Procedures
- Screening
- High Risk Women
- Communication
- Multidisciplinary Team Meeting
- Take-Home Messages
- References
- Test Your Knowledge

/ Breast Imaging

CHAPTER OUTLINE:

Breast Anatomy

Anatomical Variants

Pregnancy and Lactation

Diagnostic Imaging Techniques

/ US

Disease of the Breast:
Benign

Disease of the Breast:
Malignant

Axilla

Interventional Procedures

Screening

High Risk Women

Communication

Multidisciplinary Team
Meeting

Take-Home Messages

References

Test Your Knowledge

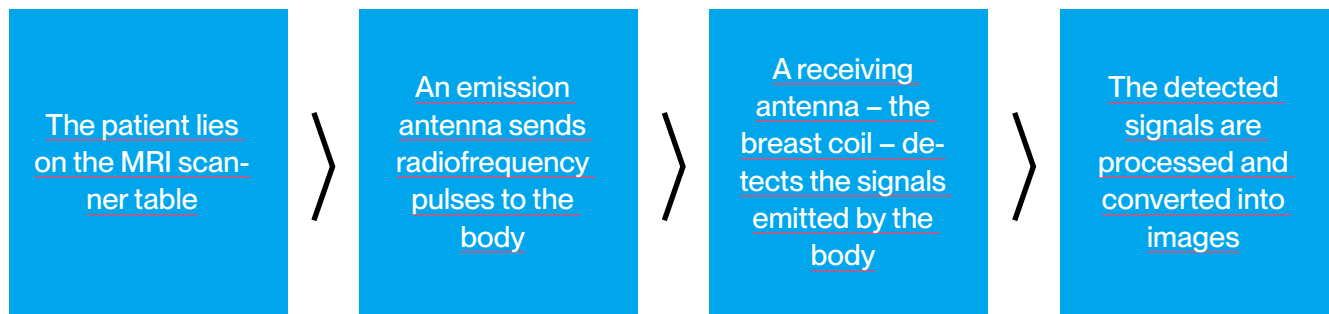
Main Indications

- / Complementary assessment of findings detected by other imaging techniques (e.g., mammographically-detected masses and asymmetries, “second look” US after MRI).
- / Evaluation of lymph nodes in level 1, 2 and 3 of the axilla.
- / Evaluation of palpable abnormalities – direct real-time correlation of imaging and clinical findings:
 - / Particularly in women with dense breasts (women with higher proportion of fibroglandular tissue) – Mammography is less sensitive.
- / Evaluation of symptomatic young (usually < 30 years of age) or lactating and pregnant women.
- / Guiding biopsies and other interventional procedures (e.g., aspiration of cysts, abscesses).

/ Magnetic Resonance Imaging (MRI)

Principles

- / Breast MRI is an imaging technique that exploits the magnetism of the protons that constitute the breast (and surrounding) tissues to create diagnostic images.
- / In simple terms, breast MRI results from this sequence of events



<!=> ATTENTION

- > See also eBook chapter on Magnetic Resonance Imaging

/ Breast Imaging

CHAPTER OUTLINE:

- Breast Anatomy
- Anatomical Variants
- Pregnancy and Lactation
- Diagnostic Imaging Techniques**
 - / MRI
- Disease of the Breast: Benign
- Disease of the Breast: Malignant
- Axilla
- Interventional Procedures
- Screening
- High Risk Women
- Communication
- Multidisciplinary Team Meeting
- Take-Home Messages
- References
- Test Your Knowledge

The main sequences acquired in Breast MRI are:

- / **T1-weighted sequences (T1W)** without and/or with fat saturation, before and after intravenous administration of gadolinium-based contrast agent – dynamic contrast-enhanced (DCE) imaging. > **Applications:** Anatomy evaluation; DCE - Assessment of vascularisation
- / **T2-weighted sequences (T2W)** without and/or with fat saturation > **Applications:** Detection of fluid (cysts, oedema.) – high signal intensity; Evaluation of the ductal system – normally high signal intensity

- / **Diffusion-weighted imaging (DWI)** > **Applications:** Further characterisation of findings by evaluating the motion of water molecules in tissues - in highly cellular tissues (vs low cellular tissues), such as malignant lesions, there is restriction of the diffusion of water molecules, which is translated as a lower diffusion coefficient (**hindered diffusion**) in the image

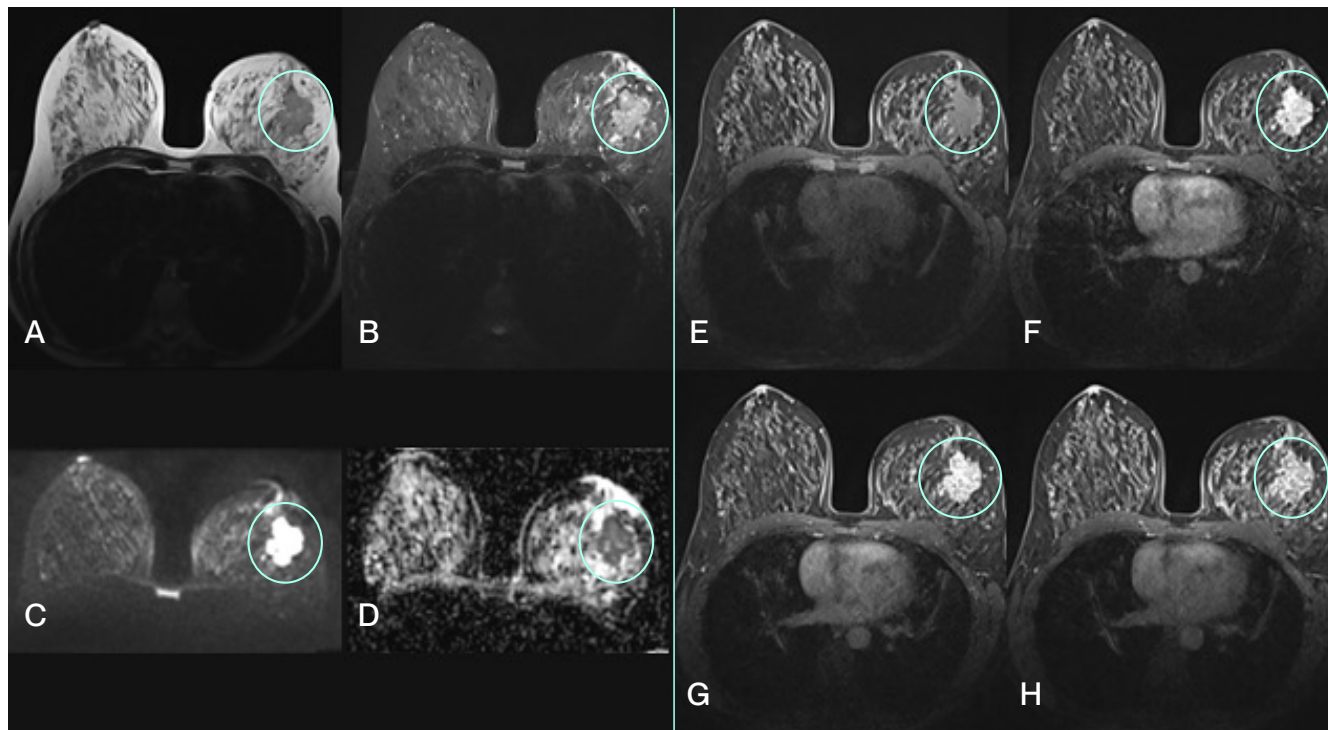
<!> **ATTENTION**

- > See also eBook chapters on Magnetic Resonance Imaging and Contrast Agents

/ Breast Imaging

CHAPTER OUTLINE:

- Breast Anatomy
- Anatomical Variants
- Pregnancy and Lactation
- Diagnostic Imaging Techniques**
 - / MRI
 - Disease of the Breast: Benign
 - Disease of the Breast: Malignant
 - Axilla
 - Interventional Procedures
 - Screening
 - High Risk Women
 - Communication
 - Multidisciplinary Team Meeting
 - Take-Home Messages
 - References
 - Test Your Knowledge



Breast MRI: T2-weighted sequences – without (A) and with (B) fat saturation –, Diffusion-weighted imaging (C) with apparent diffusion coefficient (ADC) map (D) and T1-weighted sequences with fat saturation before (E) and after (F-H) intravenous administration of gadolinium-based contrast agent showing a biopsy-proven invasive breast cancer presenting as a mass with irregular margins located in the outer left breast quadrants (green circle) with heterogeneous internal enhancement (H) and perilesional oedema (B).

Breast Imaging

CHAPTER OUTLINE:

Breast Anatomy
Anatomical Variants
Pregnancy and Lactation

Diagnostic Imaging Techniques

/ MRI

Disease of the Breast:
Benign

Disease of the Breast:
Malignant

Axilla

Interventional Procedures

Screening

High Risk Women

Communication

Multidisciplinary Team
Meeting

Take-Home Messages

References

Test Your Knowledge

Relative Diagnostic Value

>|< COMPARE

MAIN ADVANTAGES:

- + Non-ionising radiation
- + High sensitivity (up to 99%)
- + Superior soft-tissue contrast
- + Further characterisation of breast lesions by using morphological and functional information (DCE and DWI)

MAIN DISADVANTAGES:

- Less available
- More expensive
- Longer scanning times – motion artefacts
- Limited use in certain circumstances – e.g., claustrophobia and certain metallic devices

/ Breast Imaging

CHAPTER OUTLINE:

Breast Anatomy

Anatomical Variants

Pregnancy and Lactation

Diagnostic Imaging Techniques

/ MRI

Disease of the Breast: Benign

Disease of the Breast: Malignant

Axilla

Interventional Procedures

Screening

High Risk Women

Communication

Multidisciplinary Team Meeting

Take-Home Messages

References

Test Your Knowledge

/ Breast Imaging

Main Indications

- / Breast cancer staging;
- / Evaluation of response to neoadjuvant therapy;
- / "Problem solving" (eg. Unclear findings in Digital Mammography, DBT and US; evaluation of suspicious nipple discharge);
- / High-risk screening (eg. BRCA1 and BRCA2 mutations carriers);
- / Screening of women with extremely dense breasts;
- / Carcinoma of unknown primary (CUP) syndrome;
- / Evaluation of breast implants.

CHAPTER OUTLINE:

Breast Anatomy

Anatomical Variants

Pregnancy and Lactation

Diagnostic Imaging Techniques

/ MRI

Disease of the Breast:
Benign

Disease of the Breast:
Malignant

Axilla

Interventional Procedures

Screening

High Risk Women

Communication

Multidisciplinary Team
Meeting

Take-Home Messages

References

Test Your Knowledge

/ Contrast-Enhanced Mammography (CEM)

CEM is an imaging technique based on dual-energy mammographic acquisition after intravenous administration of an iodinated contrast agent; it highlights areas of increased contrast agent uptake:

Typically, 90-150 mL of an iodinated contrast agent is administered via a cannula placed in the antecubital fossa, followed by administration of 20 ml of saline solution at the same rate.

At least 120 seconds after the administration of the contrast agent, two images are produced for each compression/view:

- / A **low energy image** (below the k-edge of iodine)
– equivalent to a standard Digital Mammogram
- / A **high energy image** (above the k-edge of iodine)
and resulting recombined image – the background breast tissue is suppressed to highlight areas of increased contrast agent uptake

/ Breast Imaging

CHAPTER OUTLINE:

Breast Anatomy

Anatomical Variants

Pregnancy and Lactation

Diagnostic Imaging Techniques

/ CEM

Disease of the Breast:
Benign

Disease of the Breast:
Malignant

Axilla

Interventional Procedures

Screening

High Risk Women

Communication

Multidisciplinary Team
Meeting

Take-Home Messages

References

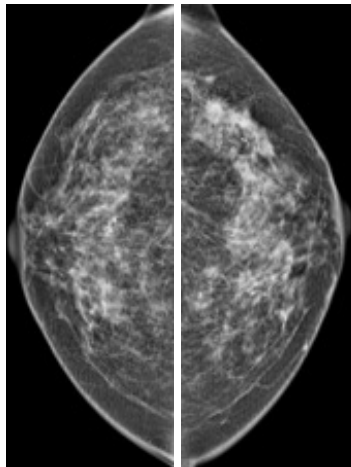
Test Your Knowledge

Breast Imaging

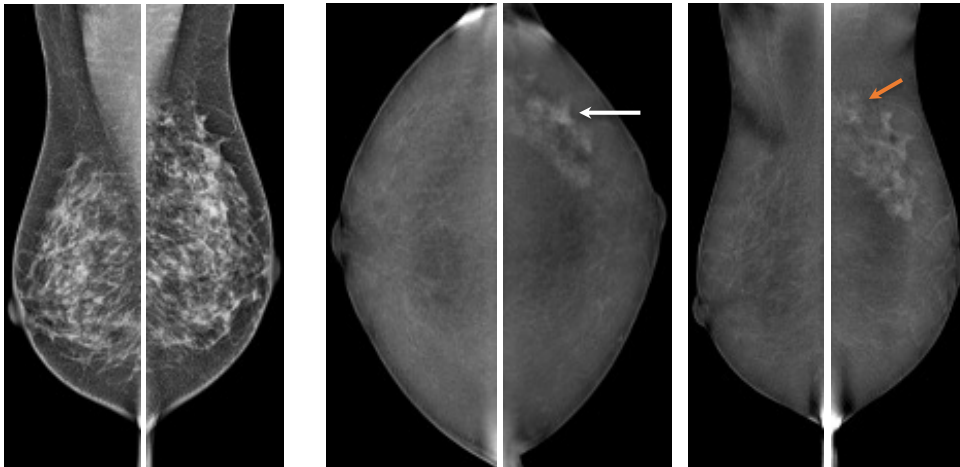
CHAPTER OUTLINE:

- Breast Anatomy
- Anatomical Variants
- Pregnancy and Lactation
- Diagnostic Imaging Techniques**
 - / CEM
- Disease of the Breast: Benign
- Disease of the Breast: Malignant
- Axilla
- Interventional Procedures
- Screening
- High Risk Women
- Communication
- Multidisciplinary Team Meeting
- Take-Home Messages
- References
- Test Your Knowledge

Low energy images



Recombined images



CEM: Low energy images show segmental pleomorphic microcalcifications in the upper outer quadrant of the left breast – further stereotactic-guided biopsy revealed Ductal Carcinoma in situ (DCIS); recombined images show coexistent but more extensive segmental clumped non-mass enhancement (white arrow), reaching the axillary tail (orange arrow).

Relative Diagnostic Value

- / CEM is more sensitive and specific than standard Digital Mammography due to the vascularity assessment.
- / Studies comparing CEM and Breast MRI have found similar sensitivities but variable specificities.

>|< COMPARE

MAIN ADVANTAGES:

compared to breast MRI

- + Lower cost
- + Shorter scanning times

MAIN DISADVANTAGES:

compared to breast MRI

- Limited Field of View (FoV) – cannot assess most of the axilla or chest wall
- Ionising radiation
- Adverse reactions to iodinated contrast agents

/ Breast Imaging

CHAPTER OUTLINE:

Breast Anatomy

Anatomical Variants

Pregnancy and Lactation

Diagnostic Imaging Techniques

/ CEM

Disease of the Breast:
Benign

Disease of the Breast:
Malignant

Axilla

Interventional Procedures

Screening

High Risk Women

Communication

Multidisciplinary Team
Meeting

Take-Home Messages

References

Test Your Knowledge

>|< COMPARE

Relative Diagnostic Value/Main Indications

The EUSOBI recommendations state that CEM can be considered as an alternative to Breast MRI for women with contraindications (eg. claustrophobia, metallic devices):

- / Although investigation on Indications is still ongoing, they are generically similar to those of Breast MRI:
 - / Breast cancer staging
 - / Evaluation of response to neoadjuvant therapy
 - / "Problem solving"

/ **Breast
Imaging**

CHAPTER OUTLINE:

Breast Anatomy

Anatomical Variants

Pregnancy and Lactation

**Diagnostic Imaging
Techniques**

/ CEM

Disease of the Breast:
BenignDisease of the Breast:
Malignant

Axilla

Interventional Procedures

Screening

High Risk Women

Communication

Multidisciplinary Team
Meeting

Take-Home Messages

References

Test Your Knowledge

CHAPTER OUTLINE:

Breast Anatomy

Anatomical Variants

Pregnancy and Lactation

Diagnostic Imaging
Techniques

**Disease of the Breast:
Benign**

Disease of the Breast:
Malignant

Axilla

Interventional Procedures

Screening

High Risk Women

Communication

Multidisciplinary Team
Meeting

Take-Home Messages

References

Test Your Knowledge

/ Diseases of the Breast: Benign

/ Cysts

- / Cysts are fluid-filled round or oval masses lined by epithelium.
- / **Most common mass in female breast**, Can occur at any age; peak prevalence: 35-50 years.
- / Patient can feel generalised or focal tenderness/pain (↑ during premenstrual phase of cycle).
- / Can be anywhere in breast, but very rare in the axilla.
- / Simple cysts have **no malignant potential**.

Complicated breast cyst: contains intracystic echoes or debris with other features of a simple cyst

Complex breast cyst ("solid and cystic mass"): thick walled with thick septa or an intracystic solid mass, can have a malignant potential!

<=> ATTENTION

Cyst is the most common mass in the female breast.

/ Breast Imaging

CHAPTER OUTLINE:

- Breast Anatomy
- Anatomical Variants
- Pregnancy and Lactation
- Diagnostic Imaging Techniques
- Disease of the Breast: Benign**
 - / Cysts
- Disease of the Breast: Malignant
- Axilla
- Interventional Procedures
- Screening
- High Risk Women
- Communication
- Multidisciplinary Team Meeting
- Take-Home Messages
- References
- Test Your Knowledge

/ Cysts – Imaging

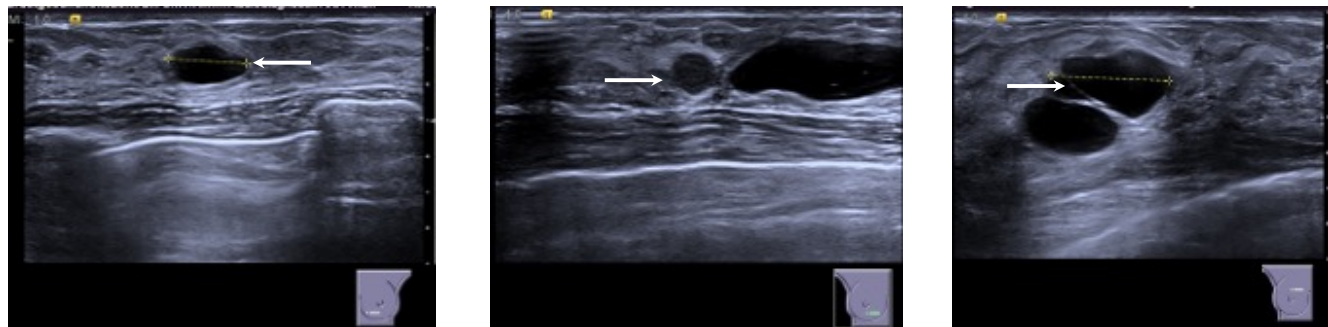
Best diagnostic tool is ultrasound (US).

- / Circumscribed, oval or round, anechoic mass with imperceptible wall and posterior enhancement
- / Can be deformable with transducer compression (not observed with solid masses)
- / Power or colour Doppler > Absent flow: Internal vascularity excludes simple cyst

<=> ATTENTION

US-guided fine-needle aspiration (FNA) is only useful in case of symptoms/signs of inflammation to reduce the symptoms as cysts can recur.

If a solid component is suspected, than prefer MRI and/or biopsy (core needle or vacuum assisted).



(Left) Ultrasound in a 35-year-old woman demonstrates an oval, circumscribed, anechoic mass with posterior enhancement (i.e., a simple cyst) in the left breast (left). Same patient has group of cysts with lobulated margin and internal debris (middle) and thin septations (right) in the right breast.

/ Breast Imaging

CHAPTER OUTLINE:

- Breast Anatomy
- Anatomical Variants
- Pregnancy and Lactation
- Diagnostic Imaging Techniques
- Disease of the Breast:**
 - Benign**
 - / Cysts

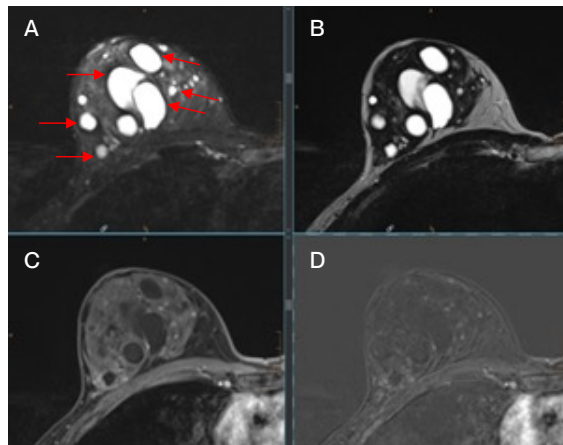
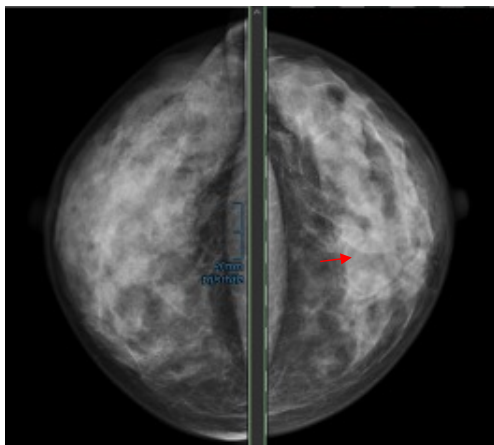
Disease of the Breast:
Malignant

- Axilla
- Interventional Procedures
- Screening
- High Risk Women
- Communication
- Multidisciplinary Team Meeting
- Take-Home Messages
- References
- Test Your Knowledge

Mammography findings: Oval or round shaped, circumscribed or partially obscured mass. The density is lower or equal to breast parenchyma.

MRI Findings:

- / **T1W:** Circumscribed, round or oval mass; low signal intensity (may have high signal if complicated).
- / **T2W:** Homogeneously hyperintense, proteinaceous content > lower signal intensity.
- / **T1W post-Gd:** No enhancement; imperceptible wall.



(Left) A 42-year-old woman noted a lump in her upper inner quadrant of left breast. On CC mammogram, the palpable finding was seen to correspond a large, partly obscured mass (arrow).

(Right) Axial STIR MR (A) (another patient) shows multiple (arrows), circumscribed, T2-hyperintense (B) oval masses due to simple cysts. Axial T1 C+ FS (C) and subtraction (D) MR shows nonenhancing cysts.

Breast Imaging

CHAPTER OUTLINE:

Breast Anatomy
Anatomical Variants
Pregnancy and Lactation
Diagnostic Imaging Techniques

Disease of the Breast: Benign

/ Cysts

Disease of the Breast: Malignant

Axilla

Interventional Procedures

Screening

High Risk Women

Communication

Multidisciplinary Team Meeting

Take-Home Messages

References

Test Your Knowledge

/ Fibrocystic Changes

The term **fibrocystic changes (FCC)** indicates a spectrum of histopathologic benign changes of the female mammary gland including cysts, fibrosis, apocrine metaplasia, calcifications, inflammation, epithelial hyperplasia, and sclerosing adenosis (SA). FCC is **not as a disease but rather** a disorder of physiological development, maturation, and involution.

Most common symptom is **mastalgia** – focal or diffuse, particularly outer breasts, changes with menstrual cycle, more commonly in women with high amount of fibroglandular tissue.

More common in premenopausal women, trend to increase with nulliparity, and later menopause.

<=> ATTENTION

Fibrocystic changes can be proliferative or non-proliferative.

- / **Nonproliferative FCC:** Periductal fibrosis, cysts, nonsclerosing adenosis are the most common findings in breast biopsies (70% of all cases). No increased risk of carcinoma.
- / **Proliferative FCC:** Intraductal hyperplasia, sclerosing adenosis, radial scars, and papillomas are associated with a relatively increased risk of developing carcinoma in either breast (1.5-2.0x).

/ Breast Imaging

CHAPTER OUTLINE:

- Breast Anatomy
- Anatomical Variants
- Pregnancy and Lactation
- Diagnostic Imaging Techniques
- Disease of the Breast: Benign**
 - / Fibrocystic Changes
- Disease of the Breast: Malignant
- Axilla
- Interventional Procedures
- Screening
- High Risk Women
- Communication
- Multidisciplinary Team Meeting
- Take-Home Messages
- References
- Test Your Knowledge

/ Fibroadenoma

Fibroadenoma (FA) is a common benign breast lesion resulting from excess proliferation of connective tissue. Fibroadenomas characteristically contain both stromal and epithelial cells.

- / Most common solid mass in women of all ages (peak incidence 25-30 years)
- / Most common sign: mobile, non-adherent palpable mass \pm tender
- / Adult and juvenile ("cellular") types
- / Natural history of FA to become sclerosed and calcify, involute spontaneously following menopause
- / Follow-up to document possible growth is required at first sight, if the lesion diameter increases by more than 20 percent within 6 months and/or develops suspicious features, biopsy is recommended. If the biopsy result is equivocal or discordant, surgical excision is indicated

<!=> ATTENTION

Fibroadenoma is the most common solid mass in women.

/ Breast Imaging

CHAPTER OUTLINE:

Breast Anatomy

Anatomical Variants

Pregnancy and Lactation

Diagnostic Imaging Techniques

Disease of the Breast: Benign

/ Fibroadenoma

Disease of the Breast: Malignant

Axilla

Interventional Procedures

Screening

High Risk Women

Communication

Multidisciplinary Team Meeting

Take-Home Messages

References

Test Your Knowledge

/ Fibroadenoma – Imaging

<=> ATTENTION

Best tool for symptomatic patients:
ultrasound if < 40y and mammography if > 40y, followed by US if needed.

>=< FURTHER KNOWLEDGE

Mammography:

- / Oval or macrolobulated, **circumscribed** (can present a halo sign).
- / Multiplicity/bilaterality may be more evident on DBT.
- / Can have calcifications (**popcorn-shaped**), very dense or large; heterogeneous calcifications often gradually ↑ and coarsen as FA involutes.

US:

- / Circumscribed, oval or gently lobulated, slightly hypo- to isoechoic mass with the long axis **parallel** to skin surface & the length:height ratio typically > 1.4 (mean: 1.8).
- / Homogeneous, low-level internal echogenicity & echogenic calcifications ± shadowing.
- / Doppler: Peripheral and feeding vessels common in juvenile fibroadenomas.

MRI:

- / **T2W:** Myxoid FA and FA in young women usually ↑ T2 signal; After menopause, sclerosis and hyalinisation → ↓ T2 signal.
- / **DWI:** Often bright with unhindered diffusion (high ADC).
- / **Contrast-enhanced T1WI:** Oval or macrolobulated, circumscribed, enhancing mass.

PET CT:

- / Common false-positive as most often FDG avid in Positron Emission Tomography.

/ Breast Imaging

CHAPTER OUTLINE:

Breast Anatomy
Anatomical Variants
Pregnancy and Lactation
Diagnostic Imaging Techniques

Disease of the Breast: Benign

/ Fibroadenoma

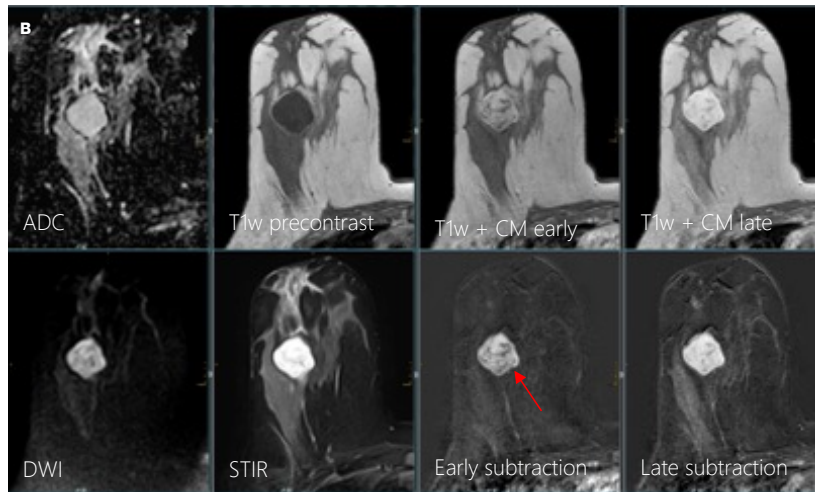
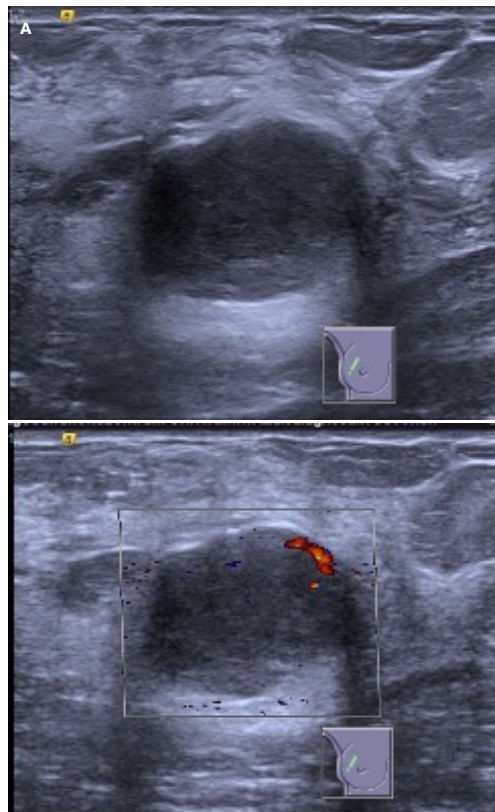
Disease of the Breast: Malignant

Axilla
Interventional Procedures
Screening
High Risk Women
Communication
Multidisciplinary Team Meeting
Take-Home Messages
References
Test Your Knowledge

Breast Imaging

CHAPTER OUTLINE:

- Breast Anatomy
- Anatomical Variants
- Pregnancy and Lactation
- Diagnostic Imaging Techniques
- Disease of the Breast:**
 - Benign**
 - / Fibroadenoma
 - Disease of the Breast: Malignant**
- Axilla
- Interventional Procedures
- Screening
- High Risk Women
- Communication
- Multidisciplinary Team Meeting
- Take-Home Messages
- References
- Test Your Knowledge



(A) 9-year-old woman had a palpable lump in upper outer right breast. Targeted US show a slightly lobulated, oval mass with mild posterior enhancement. Doppler US shows peripheral vascularisation.

(B) Representative axial multiparametric MRI of the right breast (same patient) shows large, enhancing (persistent signal increase), circumscribed, oval mass with dark internal septations (arrow).

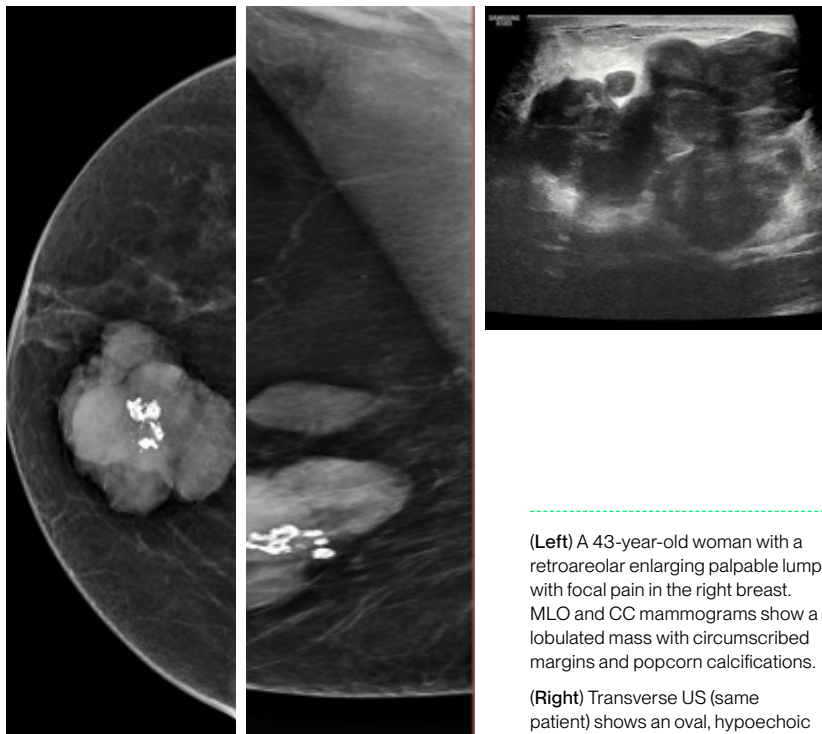
/ Phyllodes Tumour

Phyllodes tumour is a rare fibroepithelial tumour of the breast which **resembles fibroadenoma**.

It is typically a **large, fast growing** mass (3-5 cm at presentation) that forms from the periductal stroma of the breast.

Pathological distinction between fibroadenoma and phyllodes tumour is based on cellularity and overgrowth of stroma, margins, and mitotic figures.

- / Imaging **cannot** reliably distinguish fibroadenoma from benign phyllodes tumour.
- / Complete surgical excision is curative with wide local excision.



(Left) A 43-year-old woman with a retroareolar enlarging palpable lump with focal pain in the right breast. MLO and CC mammograms show a lobulated mass with circumscribed margins and popcorn calcifications.

(Right) Transverse US (same patient) shows an oval, hypoechoic mass with lobulated margins. Core biopsy = "fibroepithelial lesion." Excision = "benign PT".

/ Breast Imaging

CHAPTER OUTLINE:

- Breast Anatomy
- Anatomical Variants
- Pregnancy and Lactation
- Diagnostic Imaging Techniques
- Disease of the Breast: Benign**
 - / Phylloides Tumour
- Disease of the Breast: Malignant
- Axilla
- Interventional Procedures
- Screening
- High Risk Women
- Communication
- Multidisciplinary Team Meeting
- Take-Home Messages
- References
- Test Your Knowledge

/ Hamartoma

Hamartoma, also known as fibroadenolipoma, is a **focal developmental malformation**. Usually circumscribed lesion with abnormal mixture of tissue elements or abnormal proportion of single element.

- / Disorganised overgrowth of benign mammary tissue with normal differentiation of cells; variously ductal, lobular epithelium; stromal mesenchymal elements “breast within a breast”
- / Type of biphasic breast **lesion**: contains integral epithelial and stromal components
- / **Typically** benign finding, BI-RADS 2
- / Core biopsy: Rarely indicated
- / Usually asymptomatic, found on screening; can present as vague breast mass, can enlarge

<∞> REFERENCE

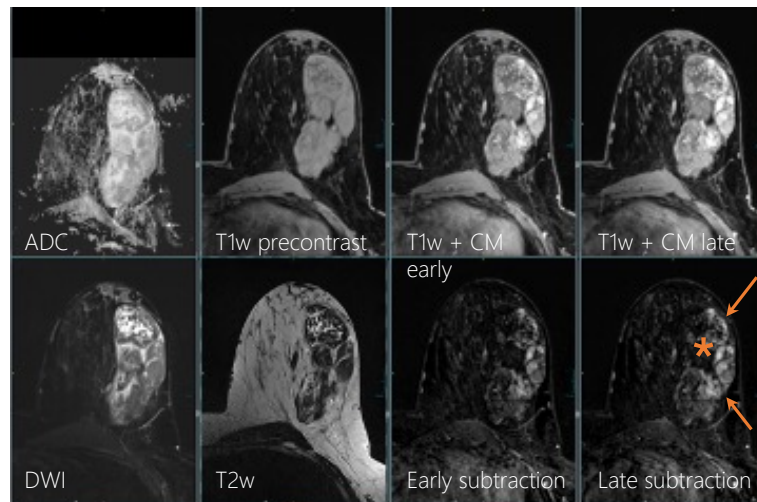
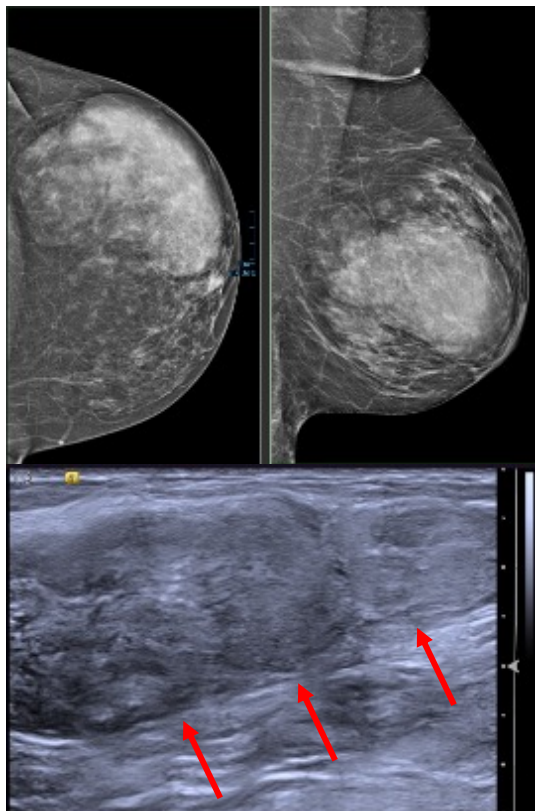
<https://www.ncbi.nlm.nih.gov/pmc/articles/PMC4886616/>

/ Breast Imaging

CHAPTER OUTLINE:

- Breast Anatomy
- Anatomical Variants
- Pregnancy and Lactation
- Diagnostic Imaging Techniques
- Disease of the Breast: Benign**
 - / Hamartoma
- Disease of the Breast: Malignant
- Axilla
- Interventional Procedures
- Screening
- High Risk Women
- Communication
- Multidisciplinary Team Meeting
- Take-Home Messages
- References
- Test Your Knowledge

/ Hamartoma – Imaging



(Left) CC and MLO mammogram in a 41-year-old woman with asymmetric left breast shows a superficial 10-cm, oval, circumscribed mass. The mass is composed of mixed fat and fibroglandular elements surrounded by a pseudocapsule, consistent with hamartoma. US (same patient) shows a corresponding isoechoic oval mass with pseudocapsule (arrows).

(Right) MRI (same patient) performed to evaluate left breast mass showing a circumscribed, oval mass with persistent enhancing fibroglandular elements (arrow) and nonenhancing fat (asterisk).

/ Breast Imaging

CHAPTER OUTLINE:

- Breast Anatomy
- Anatomical Variants
- Pregnancy and Lactation
- Diagnostic Imaging Techniques
- Disease of the Breast: Benign**
 - / Hamartoma
- Disease of the Breast: Malignant
- Axilla
- Interventional Procedures
- Screening
- High Risk Women
- Communication
- Multidisciplinary Team Meeting
- Take-Home Messages
- References
- Test Your Knowledge

/ Lipoma and Angiolipoma

Lipoma is a benign neoplasm composed of mature adipose cells.

Angiolipoma is a benign fatty neoplasm with capillary networks and fibrin thrombi.

Most common signs/symptoms:

- / Slow-growing, freely movable, soft mass
- / Subcutaneous lipomas more frequently palpable + painless
- / Multiple lipomas may occur bilaterally in 3%

Angiolipoma: 5-17% of benign fatty tumours, more common in the upper extremities, abdomen, back

Differential Diagnosis:

- / Benign Fat-Containing Lesions
 - / Fibroadenolipoma (hamartoma)
 - / Fat necrosis
 - / Hibernoma
 - / Cosmetic fat grafting or injections
- / Liposarcoma and Atypical Lipoma

<!> ATTENTION

Lipoma is the most common soft tissue tumour in adults.

/ Breast Imaging

CHAPTER OUTLINE:

- Breast Anatomy
- Anatomical Variants
- Pregnancy and Lactation
- Diagnostic Imaging Techniques
- Disease of the Breast: Benign**
 - / Lipoma and Angiolipoma
- Disease of the Breast: Malignant
- Axilla
- Interventional Procedures
- Screening
- High Risk Women
- Communication
- Multidisciplinary Team Meeting
- Take-Home Messages
- References
- Test Your Knowledge

/ Lipoma and Angiolipoma – Imaging

Mammographic Findings:

- / **Lipoma:** Fat-only (radiolucent), **circumscribed**, oval or round mass;
- / **Mass effect** on surrounding tissue (displaces vessels, muscle, nodes).
- / **Angiolipoma:** Circumscribed, fat-containing mass; may show soft tissue density due to capillary networks, fibrin thrombi.

US Findings:

- / **Lipoma:** Circumscribed, oval or round mass;
 - / Slightly **hyperechoic or isoechoic** to subcutaneous fat.
 - / Compresses/displaces adjacent muscle, glandular tissue.
- / **Angiolipoma:** Circumscribed **usually hyperechoic** mass, may have hypoechoic foci.
- / **Both:** Little or no internal vascularity on Doppler.

MRI Findings:

- / **Lipoma:** Circumscribed, T1-hyperintense, nonenhancing fatty mass.
- / **Angiolipoma:** Circumscribed nonenhancing fatty mass, may contain hypointense foci on T1W & T2W sequences.

/ Breast Imaging

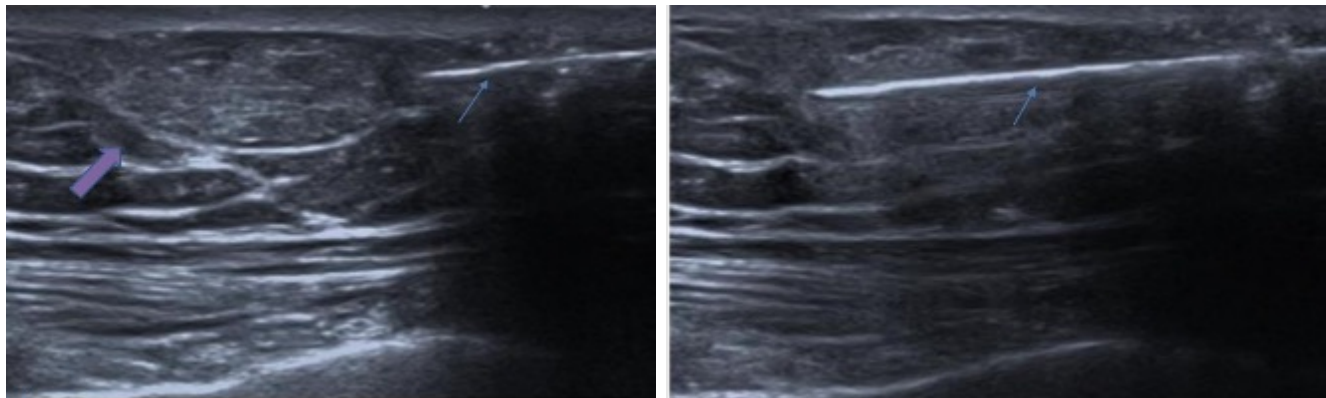
CHAPTER OUTLINE:

- Breast Anatomy
- Anatomical Variants
- Pregnancy and Lactation
- Diagnostic Imaging Techniques
- Disease of the Breast: Benign**
 - / Lipoma and Angiolipoma
- Disease of the Breast: Malignant
- Axilla
- Interventional Procedures
- Screening
- High Risk Women
- Communication
- Multidisciplinary Team Meeting
- Take-Home Messages
- References
- Test Your Knowledge

/ Breast Imaging

CHAPTER OUTLINE:

- Breast Anatomy
- Anatomical Variants
- Pregnancy and Lactation
- Diagnostic Imaging Techniques
- Disease of the Breast:**
 - Benign**
 - / Lipoma and Angiolipoma
 - Disease of the Breast:**
 - Malignant**
- Axilla
- Interventional Procedures
- Screening
- High Risk Women
- Communication
- Multidisciplinary Team Meeting
- Take-Home Messages
- References
- Test Your Knowledge



(Left) 39-year-old woman had a longstanding palpable lump in her right breast. US shows an elongated, oval, circumscribed mass (purple arrow) without internal vascularity, which was isoechoic or very slightly hyperechoic to the subcutaneous fat, consistent with benign lipoma. (Right) US-guided biopsy concordant.

/ Mastitis

Mastitis = focal or diffuse breast inflammation, usually infectious. There are several distinct clinical entities:

- / **Puerperal mastitis:** in lactating breast; bacterial; **responds well** to conservative treatment & oral antibiotics
- / **Non-puerperal mastitis:** broad category of non-lactational bacterial infection; includes iatrogenic; often chronic, recurrent, refractory to conservative therapy; a special entity is granulomatous mastitis
- / Most common **causative organisms**
 - / Staphylococcus (aureus or epidermidis); methicillin-resistant S. aureus (MRSA): more localised & invasive
 - / Streptococcus: More diffuse; associated with cellulitis
- / Most **common signs/symptoms**
 - / Diffuse or focal pain/tenderness, erythema, edema, warmth
 - / Palpable, tender lump (abscess, inflammatory mass)
 - / ± nipple retraction, discharge, fever, leukocytosis

<!=> ATTENTION

Treatment

- / Oral systemic antibiotics & warm compresses, analgesics
- / If symptoms do not resolve promptly, US should be performed to exclude abscess
 - / If (+) abscess: US-guided aspiration > culture & sensitivity, pathogen-specific antibiotics
- / Repeat aspiration may be necessary

<∞> REFERENCE

<https://pmc.ncbi.nlm.nih.gov/articles/PMC4886616/>

/ Breast Imaging

CHAPTER OUTLINE:

- Breast Anatomy
- Anatomical Variants
- Pregnancy and Lactation
- Diagnostic Imaging Techniques
- Disease of the Breast: Benign**
 - / Mastitis/Abscess
- Disease of the Breast: Malignant
- Axilla
- Interventional Procedures
- Screening
- High Risk Women
- Communication
- Multidisciplinary Team Meeting
- Take-Home Messages
- References
- Test Your Knowledge

/ Mastitis/Abscess – Imaging

Mammographic Findings:

- / Not routinely performed in puerperal mastitis (clinical diagnosis).
- / Diffuse or focal: ↑ **breast density, skin & trabecular thickening**.
- / ± dilated subareolar ducts, may extend peripherally.
- / Irregular mass: **Consider abscess** or nonbacterial mastitis.
- / **Adenopathy** often present.

MRI Findings:

- / T2W: ↑ T2 signal in areas of edema;
- / **Focal T2-hyperintense collection(s) suggest abscess.**
- / T1W C+: Focal non-mass enhancement can be seen;
- / **Rim-enhancing mass** suggests abscess or malignancy.

US Findings:

- / Diffuse or focal skin thickening, ↑ **echogenicity due to edema**, ± hyperemia on Doppler.
- / ± dilated lymphatics, intraductal debris, thickened duct walls.
- / Possible fluid collection ± mobile echoes, fluid-debris level, thick wall: **Abscess.**
- / Often reactive axillary nodes with diffusely thickened cortices.

/ Breast Imaging

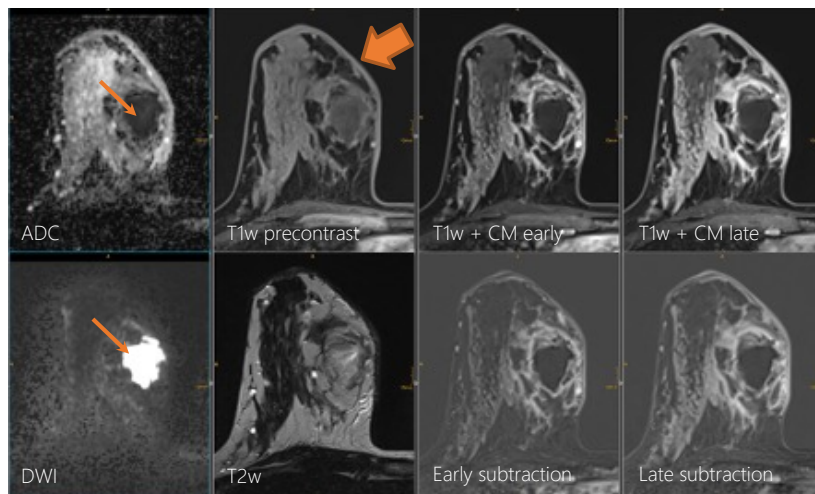
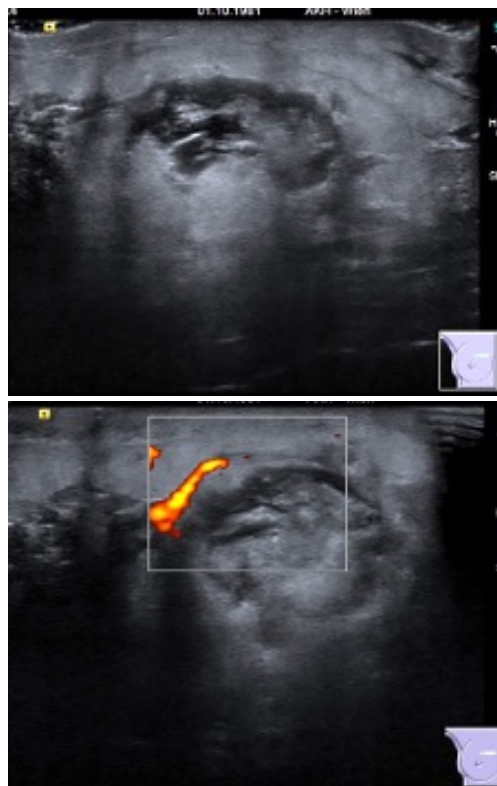
CHAPTER OUTLINE:

- Breast Anatomy
- Anatomical Variants
- Pregnancy and Lactation
- Diagnostic Imaging Techniques
- Disease of the Breast: Benign**
 - / Mastitis/Abscess
- Disease of the Breast: Malignant
- Axilla
- Interventional Procedures
- Screening
- High Risk Women
- Communication
- Multidisciplinary Team Meeting
- Take-Home Messages
- References
- Test Your Knowledge

Breast Imaging

CHAPTER OUTLINE:

- Breast Anatomy
- Anatomical Variants
- Pregnancy and Lactation
- Diagnostic Imaging Techniques
- Disease of the Breast:**
 - Benign**
 - / Mastitis/Abscess
 - Disease of the Breast: Malignant**
- Axilla
- Interventional Procedures
- Screening
- High Risk Women
- Communication
- Multidisciplinary Team Meeting
- Take-Home Messages
- References
- Test Your Knowledge



A 29-year-old woman with 2-week history of right mastitis, presents with a medial, tender lump with associated warmth and erythema.

(Upper) Targeted US shows skin thickening, a hypoechoic collection surrounded by increased echogenicity due to edema. Vessels in rim on colour Doppler imaging.

(Lower) (same patient) MRI shows intermediate-intensity fluid collection and skin edema (**thick arrow**). Diffusion hindered abscess cavity has very high DWI signal and low ADC (**thin arrow**). T1W C+ shows rim enhancing mass and skin enhancement

/ Hematoma

Hematoma is the localised collection of extravasated blood.

Etiology: Trauma, iatrogenic (biopsy, surgery), spontaneous (bleeding diathesis, anticoagulant therapy)

Signs and symptoms:

- / Painful, palpable, tender lump after known trauma or intervention; may occur spontaneously.
- / Overlying ecchymosis, skin discoloration.
- / Initially firm on palpation, may be fluctuant as hematoma evolves.

Most resolve rapidly and spontaneously **without intervention:**

- / Post-traumatic typically ≤ 6 weeks, post-lumpectomy often ≥ 1 year.
- / May evolve into fat necrosis with oil cyst formation.

<=> REFERENCE

<https://pmc.ncbi.nlm.nih.gov/articles/PMC4886616/>

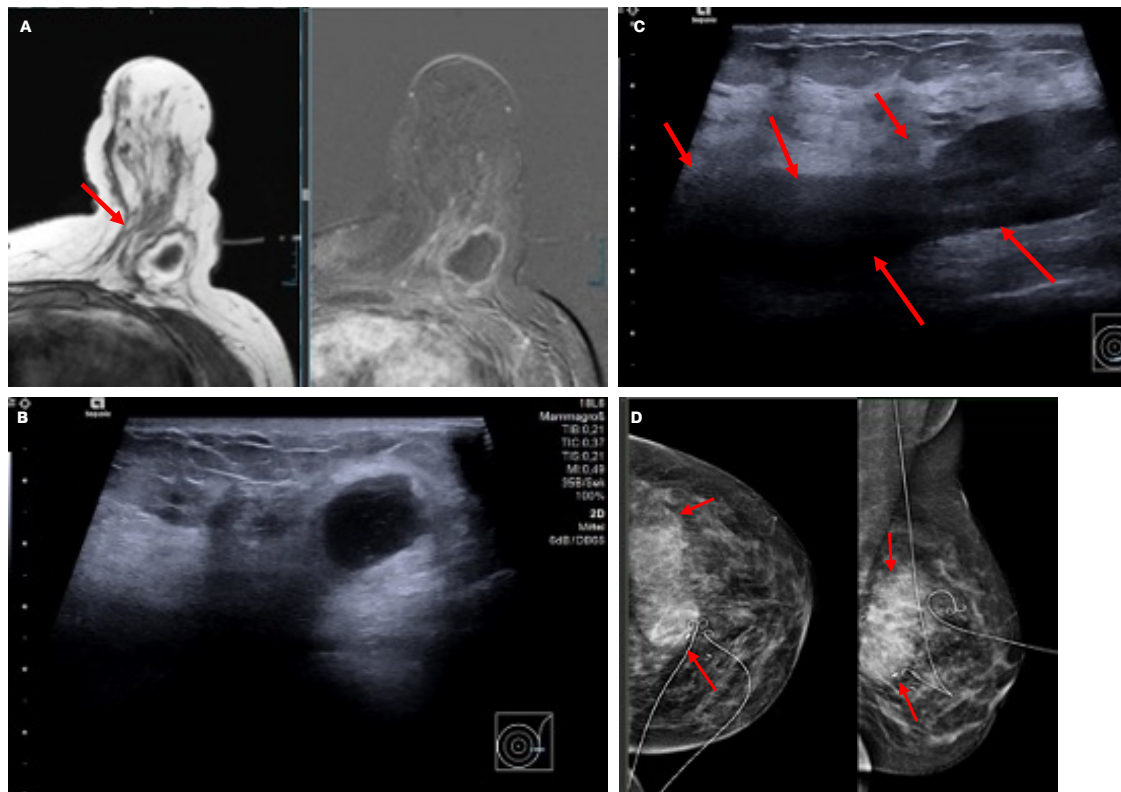
/ Breast Imaging

CHAPTER OUTLINE:

- Breast Anatomy
- Anatomical Variants
- Pregnancy and Lactation
- Diagnostic Imaging Techniques
- Disease of the Breast: Benign**
 - / Hematoma
- Disease of the Breast: Malignant
- Axilla
- Interventional Procedures
- Screening
- High Risk Women
- Communication
- Multidisciplinary Team Meeting
- Take-Home Messages
- References
- Test Your Knowledge

/ Hematoma – Imaging

<!> ATTENTION



A 44-year-old woman with left breast suspicious lesion (not shown) presented for MR-guided biopsy. MR shows a 2-cm mass with low signal on T1, and with very thin peripheral enhancement on T1 C+ (A), consistent with acute hematoma during biopsy. Targeted US from same-day right after biopsy shows mildly irregular hypoechoic mass (B).

Control US (C) performed 2 weeks later displays a 10-cm acute hematoma with internal echoes (arrows). Control MG (D), on the day of wire-marking shows a circumscribed mass lesion developed compatible with a hematoma. The position of the wires is highly debatable.

/ Breast Imaging

CHAPTER OUTLINE:

Breast Anatomy
Anatomical Variants
Pregnancy and Lactation

Diagnostic Imaging Techniques

Disease of the Breast: Benign

/ Hematoma

Disease of the Breast: Malignant

Axilla

Interventional Procedures

Screening

High Risk Women

Communication

Multidisciplinary Team Meeting

Take-Home Messages

References

Test Your Knowledge

/ Fat Necrosis

Fat necrosis within the breast is a pathological process that occurs when there is saponification of local fat. It is a benign inflammatory process and is becoming increasingly common with the greater use of breast-conserving surgery and mastoplasty procedures.

Etiology

- / No history of prior trauma or surgery in 35-50%.
- / Accidental injury (blunt or penetrating trauma).
- / Surgery/procedures (e.g. reduction mastoplasty).
- / Spontaneous development in patients with diabetes.
- / Chemical irritation (ruptured cyst or ectatic ducts).

<!=> ATTENTION

Presentation

- / Highly variable.
- / May be asymptomatic on screening.
- / Tender or nontender, palpable mass or masses.
- / Firm, fixed mass, retraction.

/ Breast Imaging

CHAPTER OUTLINE:

- Breast Anatomy
- Anatomical Variants
- Pregnancy and Lactation
- Diagnostic Imaging Techniques
- Disease of the Breast: Benign**
 - / Fat Necrosis
- Disease of the Breast: Malignant
- Axilla
- Interventional Procedures
- Screening
- High Risk Women
- Communication
- Multidisciplinary Team Meeting
- Take-Home Messages
- References
- Test Your Knowledge

/ Fat Necrosis – Imaging

Mammographic Findings:

- / Round, oval, or lobulated lucent mass;
 - / Surrounding increased density due to edema, fibrosis, inflammatory infiltrate.
 - / Develop peripheral rim calcifications over time.
- / Calcifications;
 - / Curvilinear, eggshell, at edge of oil cyst(s) or lobulated fatty mass.
 - / Calc. due to fat necrosis can develop **many years after** trauma/surgery.
 - / Coarse heterogeneous or curvilinear calc. most common; become coarser, dystrophic.
 - / Fine linear or pleomorphic Ca^{++} less common.
- / Spiculated or irregular mass/asymmetry;
 - / Due to fibrosis/desmoplastic reaction.
- / Trabecular thickening due to edema should decrease over 3-6 months.

Calcifications rarely seen < 1.5 years after trauma/surgery!!

/ Breast Imaging

CHAPTER OUTLINE:

- Breast Anatomy
- Anatomical Variants
- Pregnancy and Lactation
- Diagnostic Imaging Techniques
- Disease of the Breast: Benign**
 - / Fat Necrosis
- Disease of the Breast: Malignant
- Axilla
- Interventional Procedures
- Screening
- High Risk Women
- Communication
- Multidisciplinary Team Meeting
- Take-Home Messages
- References
- Test Your Knowledge

/ Breast Imaging

CHAPTER OUTLINE:

- Breast Anatomy
- Anatomical Variants
- Pregnancy and Lactation
- Diagnostic Imaging Techniques
- Disease of the Breast: Benign**
 - / Fat Necrosis
- Disease of the Breast: Malignant
- Axilla
- Interventional Procedures
- Screening
- High Risk Women
- Communication
- Multidisciplinary Team Meeting
- Take-Home Messages
- References
- Test Your Knowledge

US Findings:

- / Sonographic appearances **evolve** over time.
- / **Acute phase:** Within days of event– Edema of breast fat → increased echogenicity.
- / **Subacute:** ill-defined complex cystic areas within edematous fat.
- / **Late phase: (≥ 18 months)** Wall calcifies: Intense posterior shadowing, spiculated mass with echogenic rim, distortion.
- / Characteristically within **fat lobule** rather than between fat lobules.
- / Colour or **power Doppler:** Internal flow may suggest **recurrent tumour** in lumpectomy patient.

Location : Most common in areas sub-areolar and superficial areas near skin

/ Breast Imaging

CHAPTER OUTLINE:

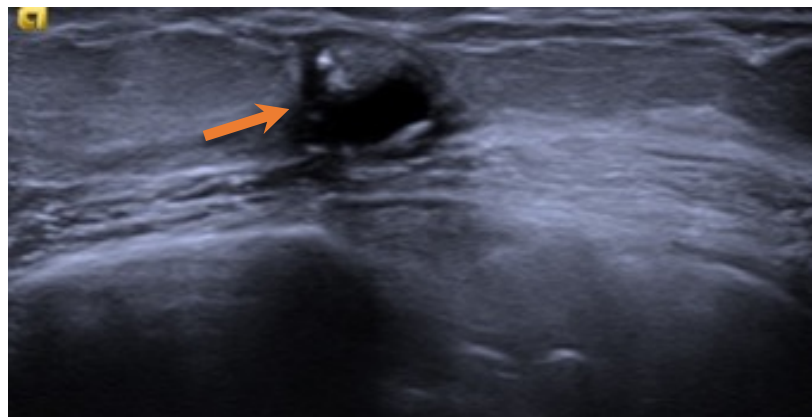
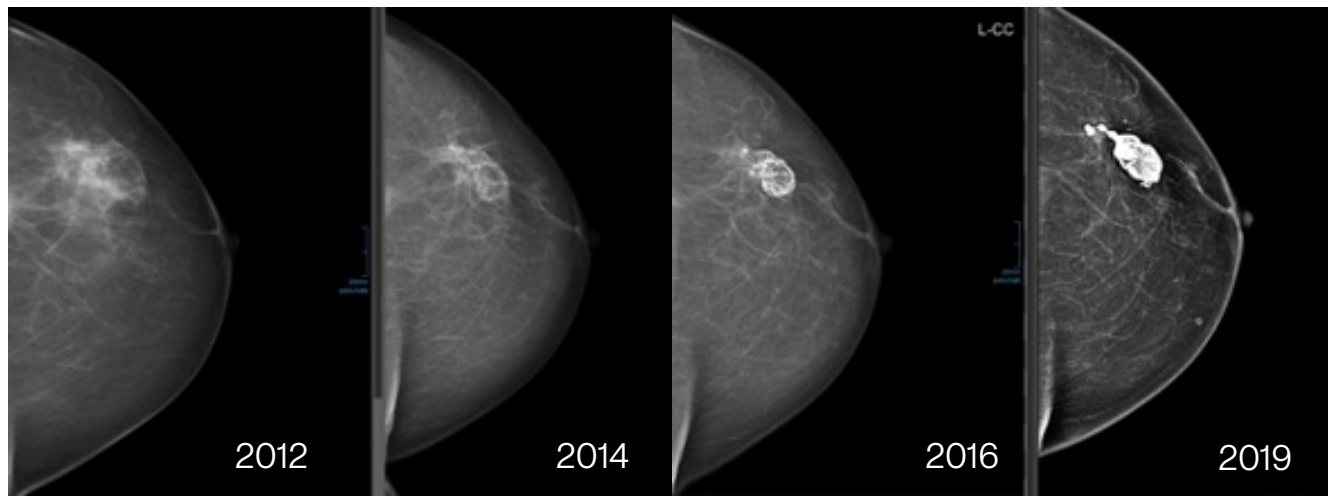
Breast Anatomy
 Anatomical Variants
 Pregnancy and Lactation
 Diagnostic Imaging Techniques
Disease of the Breast: Benign
 / Fat Necrosis
 Disease of the Breast: Malignant
 Axilla
 Interventional Procedures
 Screening
 High Risk Women
 Communication
 Multidisciplinary Team Meeting
 Take-Home Messages
 References
 Test Your Knowledge

MR Findings:

- / **T1WI:** High-signal central fat; suppresses more than normal fat on T1 FS.
- / **T2WI:** Low signal ("black hole") with fat suppression, darker than normal fat.
- / **DWI:** Unrestricted diffusion.
- / **T1WI C+**
 - / ~ 25% show no enhancement.
 - / ~ 75% thin rim of peripheral enhancement – May persist up to 5 years post trauma/surgery.

Differential diagnosis:

- / **Encapsulated Fat-Containing Lesions:** Lipoma, Fibroadenolipoma, Galactocele.
- / **Ductal Carcinoma In Situ.**
 - / Fine linear, pleomorphic Ca⁺⁺, can be similar to fat necrosis.
- / **Invasive Ductal or Lobular Carcinoma.**
 - / No history of trauma; irregular mass \pm Ca⁺⁺.



A 52-year-old woman in follow-up after left lumpectomy for DCIS. On CC (upper) mammograms, calcifying fat necrosis is seen at the lumpectomy scar over the years. Targeted US shows a centrally anechoic partially circumscribed mass with calcifications (arrow). The mass is within the subcutaneous fat.

Breast Imaging

CHAPTER OUTLINE:

Breast Anatomy
Anatomical Variants
Pregnancy and Lactation
Diagnostic Imaging Techniques

Disease of the Breast: Benign

/ Fat Necrosis

Disease of the Breast: Malignant

Axilla
Interventional Procedures
Screening
High Risk Women
Communication

Multidisciplinary Team Meeting

Take-Home Messages

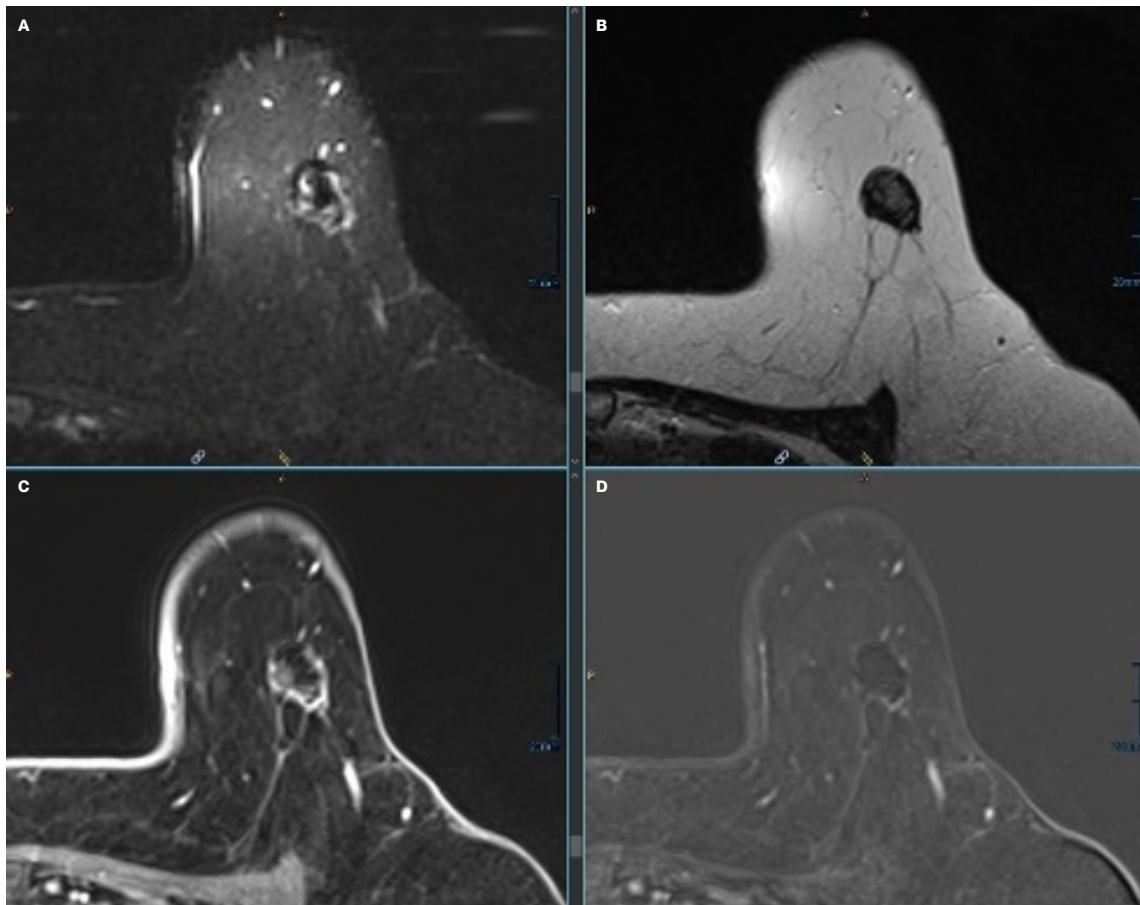
References

Test Your Knowledge

Breast Imaging

CHAPTER OUTLINE:

- Breast Anatomy
- Anatomical Variants
- Pregnancy and Lactation
- Diagnostic Imaging Techniques
- Disease of the Breast: Benign**
 - / Fat Necrosis
- Disease of the Breast: Malignant
- Axilla
- Interventional Procedures
- Screening
- High Risk Women
- Communication
- Multidisciplinary Team Meeting
- Take-Home Messages
- References
- Test Your Knowledge



Axial STIR MR (A) (same patient) shows a peripherally T2-hyperintense, oval mass with central signal void due to fat necrosis having a shorter T1 time as normal fat (which is grey). Axial T2w without fat sat (B) shows a centrally mildly hyperintense mass with internal hypointense areas (likely calcifications). Axial T1 C+ FS and subtraction (C-D) MR shows minimal non-solid rim enhancement in this mass that is centrally hypointense and lacks central enhancement. Findings are consistent with fat necrosis.

CHAPTER OUTLINE:

Breast Anatomy

Anatomical Variants

Pregnancy and Lactation

Diagnostic Imaging
Techniques

Disease of the Breast:
Benign

**Disease of the Breast:
Malignant**

Axilla

Interventional Procedures

Screening

High Risk Women

Communication

Multidisciplinary Team
Meeting

Take-Home Messages

References

Test Your Knowledge

/ Disease of the Breast: Malignant

/ Indications, Advantages and Disadvantages of Diagnostic Techniques in Malignant Breast Lesions

Mammography (diagnostic imaging, bilateral 2 views and additional views)

- / High specificity
- / Low sensitivity in dense breasts
- / High sensitivity for microcalcifications
- / Guided biopsy for mammographically detected lesions (most frequent microcalcifications)

Ultrasound (US) of bilateral breast and axilla

- / Differentiation between mass and cystic lesion
- / Low specificity
- / Biopsy guided technique for the assessment of breast lesions

Magnetic resonance imaging (MRI)

- / High sensitivity and specificity
- / Biopsy guided technique for the exploration of MRI detected lesions

<!=> ATTENTION

Mammography and US are mandatory in the investigation of all suspicious breast lesions. Additional MRI is strongly advised in case of invasive lobular carcinoma, dense breast, positive family history, gene mutation carrier and suspiciousness of multicentric or bilateral breast cancer.

/ Breast Imaging

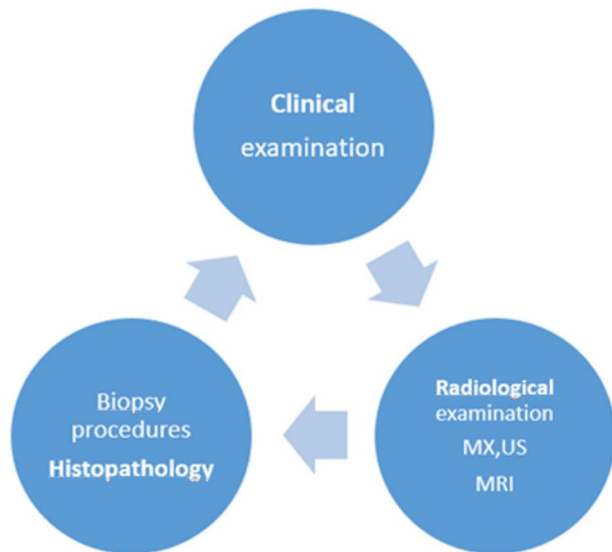
CHAPTER OUTLINE:

- Breast Anatomy
- Anatomical Variants
- Pregnancy and Lactation
- Diagnostic Imaging Techniques
- Disease of the Breast: Benign
- Disease of the Breast: Malignant**
 - / Imaging and Diagnostic Techniques
- Axilla
- Interventional Procedures
- Screening
- High Risk Women
- Communication
- Multidisciplinary Team Meeting
- Take-Home Messages
- References
- Test Your Knowledge

A **triple assessment** is mandatory for the investigation of suspicious breast lesions. It consists of a clinical examination by a trained professional, a radiological investigation and a biopsy procedure.

<!> ATTENTION

Final correlation between pathology results, clinical and imaging findings is mandatory. If a discrepancy occur, additional imaging is necessary!



A mammography (MX), ultrasound and MRI report contains a full description of both breasts, a final assessment, impression and recommendation.

A uniform description and assessment helps the radiologist to communicate about the imaging results. One of the most frequently used protocol is the Breast Imaging Reporting and Database System (BI-RADS).

In this chapter, the BI-RADS descriptors will be used to explain the presentations of malignant lesions in the breast on MX, US and MRI.

<∞> REFERENCE

<https://www.acr.org/Clinical-Resources/Clinical-Tools-and-Reference/Reporting-and-Data-Systems/BI-RADS>

/ **Breast Imaging**

CHAPTER OUTLINE:

Breast Anatomy

Anatomical Variants

Pregnancy and Lactation

Diagnostic Imaging Techniques

Disease of the Breast: Benign

Disease of the Breast: Malignant

/ Imaging and Diagnostic Techniques

Axilla

Interventional Procedures

Screening

High Risk Women

Communication

Multidisciplinary Team Meeting

Take-Home Messages

References

Test Your Knowledge

A breast imaging report contains

- / Clinical information and indication.
- / Comparison with priors (date and type of exam).
- / Breast density - Tissue composition- enhancement pattern.
- / Skin, nipple and areola.
- / Lesions;
 - / Mass, Asymmetry, Architectural distortion.
 - / Calcifications.
- / Location, size of each lesion, distance to the nipple.
- / Secondary signs (skin, nipple).
- / Lymph node status.
- / Assessment category.
- / Recommendations.

/ Breast Imaging

CHAPTER OUTLINE:

Breast Anatomy

Anatomical Variants

Pregnancy and Lactation

Diagnostic Imaging Techniques

Disease of the Breast: Benign

Disease of the Breast: Malignant

/ Imaging and Diagnostic Techniques

Axilla

Interventional Procedures

Screening

High Risk Women

Communication

Multidisciplinary Team Meeting

Take-Home Messages

References

Test Your Knowledge

<∞> REFERENCE

www.ACR.org

On mammography malignant lesions can present as a

- / Mass
- / Asymmetry
- / Architectural distortion
- / Microcalcifications

ACR BI-RADS® Atlas Fifth Edition									
QUICK REFERENCE									
MAMMOGRAPHY									
Breast composition	a. The breasts are almost entirely fatty b. There are scattered areas of fibroglandular density c. The breasts are heterogeneously dense, which may obscure small masses d. The breasts are extremely dense, which lowers the sensitivity of mammography			Calcifications	Typically benign	Skin	Asymmetries	Asymmetry	
						Vascular			Global asymmetry
Masses	Shape	Oval	Suspicious morphology	Amorphous	Intramammary lymph node				
		Round				Coarse heterogeneous	Skin lesion		
	Irregular	Fine pleomorphic	Solitary dilated duct						
	Margin	Circumscribed		Distribution	Diffuse	Associated features	Skin retraction		
		Obscured	Regional					Nipple retraction	
	Microlobulated	Grouped	Skin thickening						
	Indistinct	Linear	Trabecular thickening						
	Spiculated	Segmental	Axillary adenopathy						
	Density	High density	Architectural distortion		Location of lesion	Laterality			
		Equal density	Asymmetries	Asymmetry			Quadrant and clock face		
	Low density		Global asymmetry	Depth					
	Fat-containing		Focal asymmetry	Distance from the nipple					
			Developing asymmetry						

Breast Imaging

CHAPTER OUTLINE:

- Breast Anatomy
- Anatomical Variants
- Pregnancy and Lactation
- Diagnostic Imaging Techniques
- Disease of the Breast: Benign
- Disease of the Breast: Malignant
- / Imaging and Diagnostic Techniques

- Axilla
- Interventional Procedures
- Screening
- High Risk Women
- Communication
- Multidisciplinary Team Meeting
- Take-Home Messages
- References
- Test Your Knowledge

On **mammography** a malignant mass has an irregular shape with microlobulated, indistinct or spiculated margins. The density is higher than the surrounding tissue. Associated signs of malignancy are suspicious microcalcifications. Associated findings can be skin and nipple retraction and thickening.

Mammography

Mass:

Shape: oval (may include 2 or 3 lobulations), round, irregular

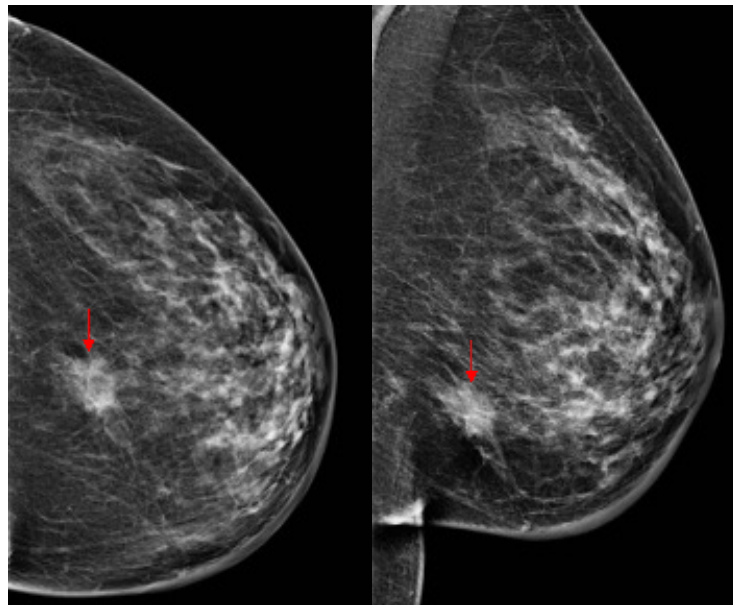
Margins: circumscribed, obscured, microlobulated, indistinct, spiculated

Density: high, equal, low or fat-containing

Associated microcalcifications

Associated findings: skin thickening

Location (left/right, quadrant, clock-wise, periareolar, middle, posterior)



Mass lesion (arrow) with an irregular shape, spiculated margins and high density. Skin thickening of the inner and lower part of the breast. Pathology showed an invasive ductal carcinoma 25 mm in size.

<∞> REFERENCE

www.ACR.org

/ Breast Imaging

CHAPTER OUTLINE:

Breast Anatomy

Anatomical Variants

Pregnancy and Lactation

Diagnostic Imaging Techniques

Disease of the Breast: Benign

Disease of the Breast: Malignant

/ Imaging and Diagnostic Techniques

Axilla

Interventional Procedures

Screening

High Risk Women

Communication

Multidisciplinary Team Meeting

Take-Home Messages

References

Test Your Knowledge

- / **Microcalcifications** can be associated with a malignant mass, or asymmetry or architectural distortion, but can also be present as the only finding in ductal carcinoma in situ.
- / The amount, type and distribution of microcalcifications should be analysed: fine linear or branching microcalcifications in a linear and segmental distributions are very suspicious for ductal carcinoma in situ (DCIS).


Mammography

Microcalcifications:

Morphology: fine-linear branching

Distribution: linear and segmental

Change over time: stability over time of suspicious calcifications is unreliable



<∞> REFERENCE

www.ACR.org

Breast Imaging

CHAPTER OUTLINE:

Breast Anatomy

Anatomical Variants

Pregnancy and Lactation

Diagnostic Imaging Techniques

Disease of the Breast: Benign

Disease of the Breast: Malignant

/ Imaging and Diagnostic Techniques

Axilla

Interventional Procedures

Screening

High Risk Women

Communication

Multidisciplinary Team Meeting

Take-Home Messages

References

Test Your Knowledge

/ Breast Imaging

CHAPTER OUTLINE:

Breast Anatomy
Anatomical Variants
Pregnancy and Lactation

Diagnostic Imaging
Techniques

Disease of the Breast:
Benign

Disease of the Breast: Malignant

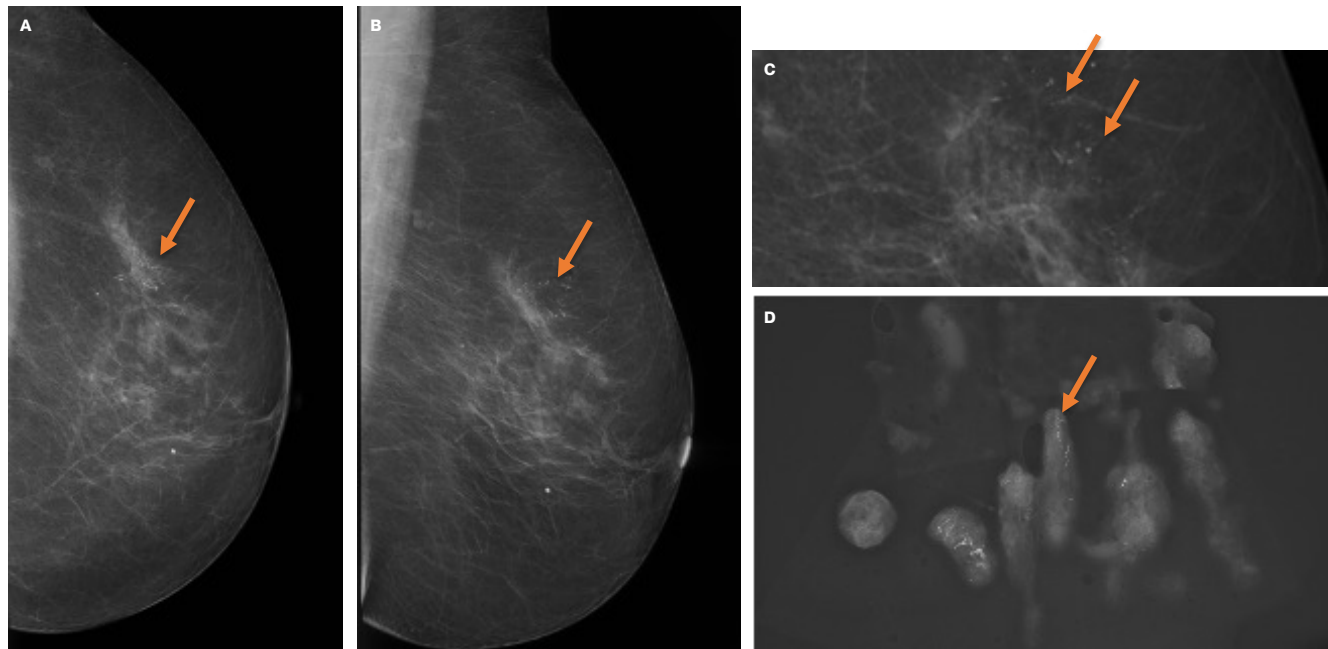/ Imaging and Diagnostic
Techniques

Axilla
Interventional Procedures
Screening
High Risk Women
Communication
Multidisciplinary Team
Meeting

Take-Home Messages

References

Test Your Knowledge



(A and B) CC and MLO view of the left breast show a segmental distribution of microcalcifications in the upper outer quadrant, pathology: ductal carcinoma in situ (DCIS)

(C) Magnification view in MLO shows fine linear branching calcifications, organised in a ductal pattern, in a segmental distribution

(D) Specimen (magnification) image shows the irregular branching or casting calcifications

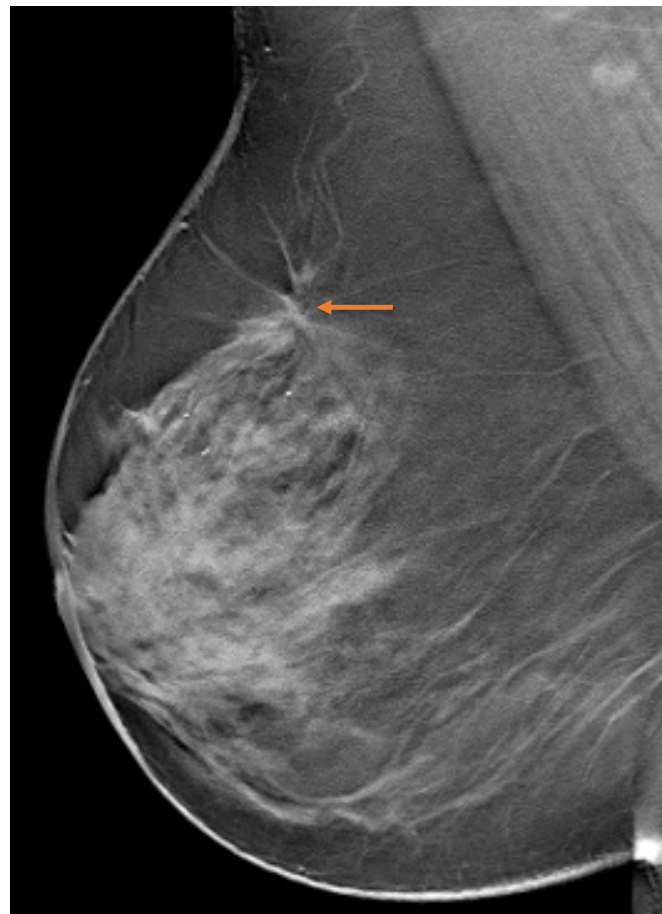
<∞> REFERENCE

www.ACR.org

Mammography

Architectural distortion:

Thin straight lines or spiculations radiating from a central area, and focal retraction, distortion or straightening at the edges of the parenchyma



MLO tomo view of the right breast shows a small distortion in the upper quadrants (arrow); pathology revealed an invasive ductal carcinoma of 1.8cm.

<!> ATTENTION

<∞> REFERENCE

www.ACR.org

Breast Imaging

CHAPTER OUTLINE:

- Breast Anatomy
- Anatomical Variants
- Pregnancy and Lactation
- Diagnostic Imaging Techniques
- Disease of the Breast: Benign
- Disease of the Breast: Malignant**
 - / Imaging and Diagnostic Techniques
- Axilla
- Interventional Procedures
- Screening
- High Risk Women
- Communication
- Multidisciplinary Team Meeting
- Take-Home Messages
- References
- Test Your Knowledge

<!> ATTENTION

Mammography

Asymmetry: area of fibroglandular tissue visible on only one mammographic projection (superimposition of normal breast tissue).

- / **Focal asymmetry** visible on two projections, hence a real finding rather than superimposition.
- / **Global asymmetry** consisting of an asymmetry over at least one quarter of the breast and is usually a normal variant.

- / **Developing asymmetry** new, larger and more conspicuous than on a previous examination. A developing asymmetry is suspicious and needs always further investigation with US and in case of discordant results, MRI.

<∞> REFERENCE

www.ACR.org

Breast Imaging

CHAPTER OUTLINE:

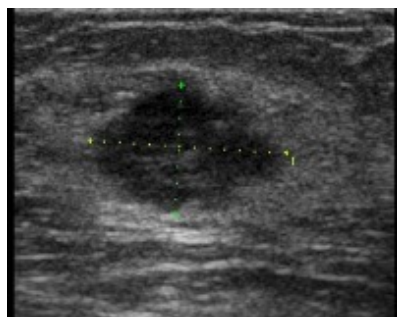
- Breast Anatomy
- Anatomical Variants
- Pregnancy and Lactation
- Diagnostic Imaging Techniques
- Disease of the Breast: Benign
- Disease of the Breast: Malignant**
 - / Imaging and Diagnostic Techniques
- Axilla
- Interventional Procedures
- Screening
- High Risk Women
- Communication
- Multidisciplinary Team Meeting
- Take-Home Messages
- References
- Test Your Knowledge

Ultrasound

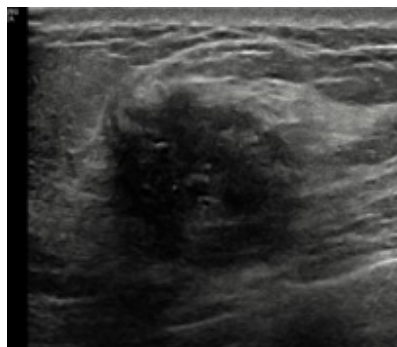
On **ultrasound** a malignant lesions is heterogeneous, hypoechoic (darker) with an irregular shape, and angular, microlobulated or spiculated margins.

The orientation is not parallel to the skin and posterior lesion shadowing is often present.

Ultrasound Lexicon		
Breast composition	a. homogeneous - fat b. homogeneous - fibroglandular c. heterogeneous	
Mass	shape	oval - round - irregular
	margin	Circumscribed or Not-circumscribed: indistinct, angular, microlobulated, spiculated
	orientation	parallel - not parallel
	echo pattern	anechoic - hyperechoic - complex cystic/solid hypoechoic - isoechoic - heterogeneous
	posterior features	no features - enhancement - shadowing - combined pattern
Calcifications	in mass - outside mass - intraductal	
Associated features	architectural distortion - duct changes - skin thickening - skin retraction - edema - vascularity (absent, internal, rim) - elasticity	
Special cases <i>(cases with a unique diagnosis)</i>	simple cyst - clustered microcysts - complicated cyst - mass in or on skin - foreign body (including implants) - intramammary lymph node - AVM - Mondor disease - postsurgical fluid collection - fat necrosis	



Ultrasound image of the mass lesion seen on MX in fig 1 shows an hypoechoic mass with an irregular shape, and microlobulated, angular margins.



Ultrasound image of the mass lesion on MX in fig 2 shows an hypoechoic mass with irregular shape, indistinct margins, with retroacoustic shadow. The reflections in the mass represent the pathological microcalcifications

Breast Imaging

CHAPTER OUTLINE:

- Breast Anatomy
- Anatomical Variants
- Pregnancy and Lactation
- Diagnostic Imaging Techniques
- Disease of the Breast: Benign
- Disease of the Breast: Malignant**
 - / Imaging and Diagnostic Techniques
- Axilla
- Interventional Procedures
- Screening
- High Risk Women
- Communication
- Multidisciplinary Team Meeting
- Take-Home Messages
- References
- Test Your Knowledge

- / If the characteristics of the lesion indicate a malignancy, BI-RADS category is 4 (4A, 4B, 4C), 5 or 6 is the final assessment.
- / Based on this classification an additional minimal invasive diagnostic technique such as a core needle biopsy must be performed (triple assessment).

BI-RADS® ASSESSMENT CATEGORIES		
Category 0: Mammography: Incomplete – Need Additional Imaging Evaluation and/or Prior Mammograms for Comparison Ultrasound & MRI: Incomplete – Need Additional Imaging Evaluation		
Category 1: Negative		
Category 2: Benign		
Category 3: Probably Benign		
Category 4: Suspicious	Mammography & Ultrasound:	Category 4A: Low suspicion for malignancy Category 4B: Moderate suspicion for malignancy Category 4C: High suspicion for malignancy
Category 5: Highly Suggestive of Malignancy		
Category 6: Known Biopsy-Proven Malignancy		
For the complete Atlas, visit acr.org/birads		

07.15

Breast Imaging

CHAPTER OUTLINE:

- Breast Anatomy
- Anatomical Variants
- Pregnancy and Lactation
- Diagnostic Imaging Techniques
- Disease of the Breast: Benign
- Disease of the Breast: Malignant**
 - / Imaging and Diagnostic Techniques
- Axilla
- Interventional Procedures
- Screening
- High Risk Women
- Communication
- Multidisciplinary Team Meeting
- Take-Home Messages
- References
- Test Your Knowledge

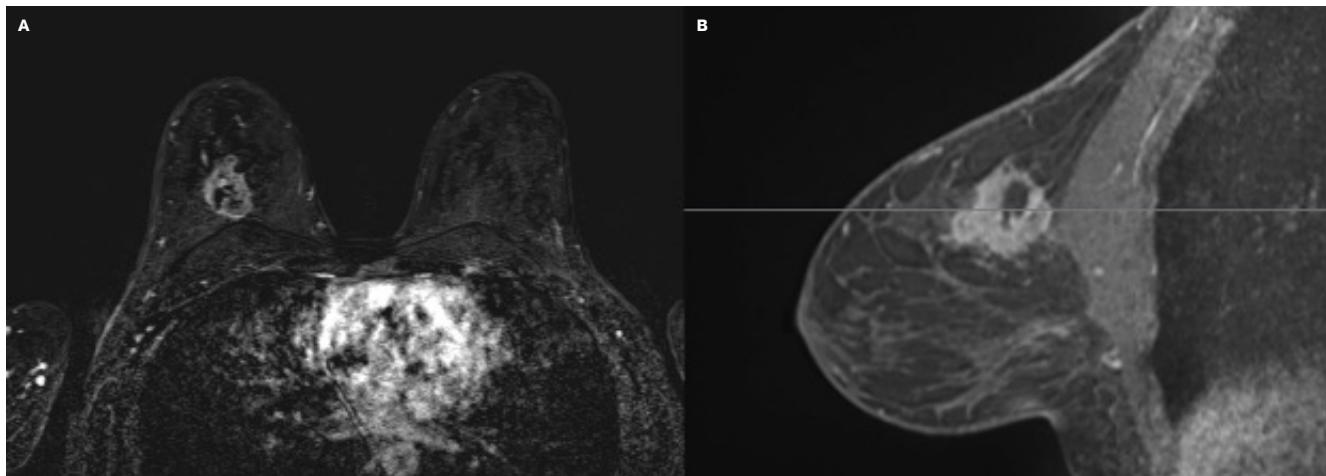
<> REFERENCE

www.ACR.org/birads

MRI

On **MRI** a malignant lesion shows a heterogeneous and rim enhancement.

The shape is irregular and margins are spiculated. Besides the morphology, the lesion shows a rapid increase in signal after the injection of contrast followed by a washout in the delayed phase.



Contrast-enhanced MRI, subtraction image axial plane (A) and T1W with fat suppression sagittal plane (B) of the tumour shows a lesion with heterogeneous and rim enhancement, the shape and margins are irregular. The pattern of enhancement is highly suspicious of malignancy.

<> REFERENCE

www.ACR.org/-/media

/ Breast Imaging

CHAPTER OUTLINE:

Breast Anatomy

Anatomical Variants

Pregnancy and Lactation

Diagnostic Imaging
Techniques

Disease of the Breast:
Benign

**Disease of the Breast:
Malignant**

/ Imaging and Diagnostic
Techniques

Axilla

Interventional Procedures

Screening

High Risk Women

Communication

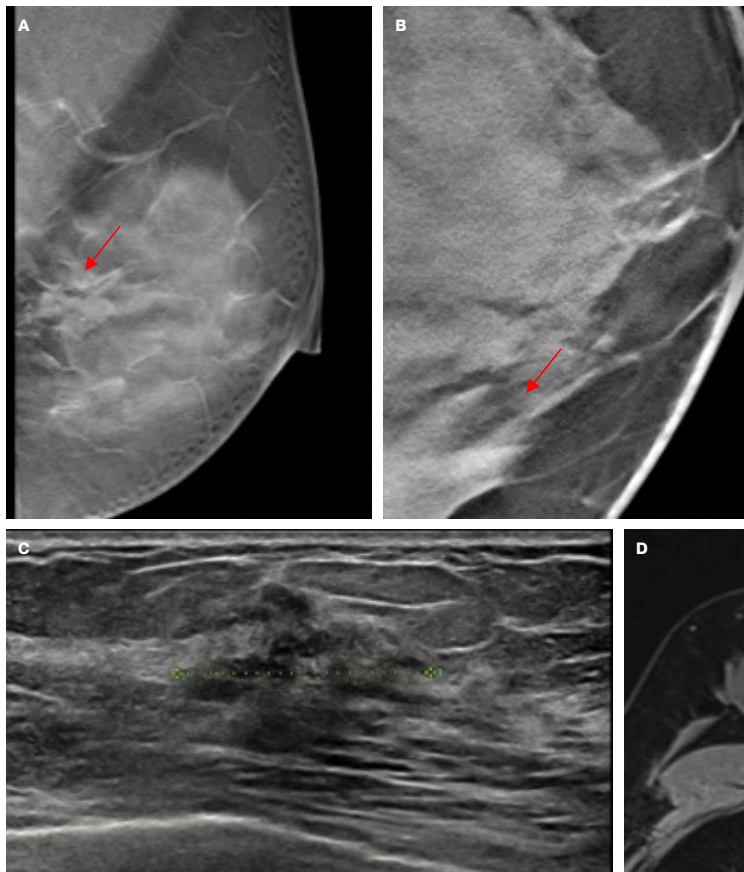
Multidisciplinary Team
Meeting

Take-Home Messages

References

Test Your Knowledge

Multimodality assessment of a malignant breast lesion



High density mass (A and B) lesion with spiculated margins and irregular shape, medial at 9 o'clock in the left breast on the digital breast tomosynthesis slices (arrow)s.

Ultrasound (C) shows an irregular lesion (between callipers), inhomogeneous, microlobulated.

On MRI (D) a strong enhancing, irregular, spiculated lesion with inhomogeneous enhancement.

Histology revealed an invasive ductal carcinoma of 2.3cm.

Breast Imaging

CHAPTER OUTLINE:

Breast Anatomy

Anatomical Variants

Pregnancy and Lactation

Diagnostic Imaging Techniques

Disease of the Breast: Benign

Disease of the Breast: Malignant

/ Imaging and Diagnostic Techniques

Axilla

Interventional Procedures

Screening

High Risk Women

Communication

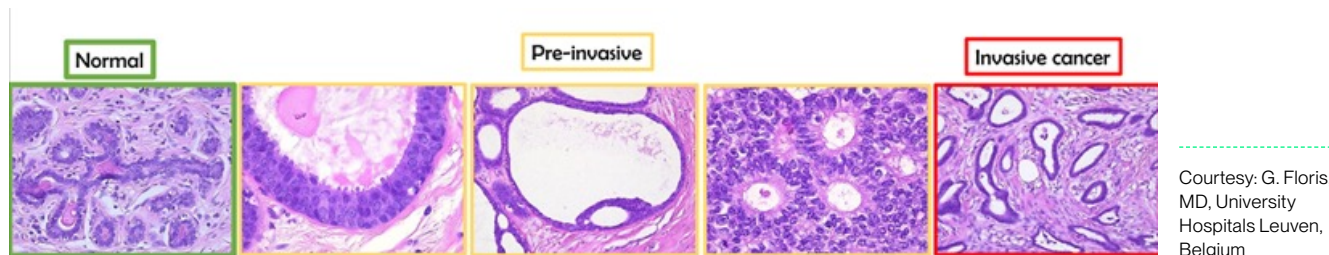
Multidisciplinary Team Meeting

Take-Home Messages

References

Test Your Knowledge

/ Histology of in Situ & Invasive Breast Cancer



- / Within the normal mammary and **terminal ductal mammary lobar unit (TDLU)**, a layer of epithelial cells and a layer of myoepithelial cells are surrounded by a basement membrane.
- / In **DCIS**, the epithelial cells are phenotypically different from normal epithelial cells (poorly differentiated DCIS more than well-differentiated DCIS). However, they are **still surrounded by a basement membrane**.

- / DCIS encompasses a group of histologically and prognostically **heterogeneous non-invasive carcinomas**. **Microcalcifications** are the main imaging finding in DCIS.
- / Once the neoplastic cells invade the basement membrane into the breast stroma, they have transitioned to an **invasive ductal carcinoma**.

<∞> REFERENCE

Breast Cancer Biology for the Radiation Oncologist, 2015; ISBN : 978-3-642-31219-9
Chapter: Biology of DCIS and progression to invasive disease.Sanaz A. Jansen
Diagnostic breast imaging, SH Heywant-Köbrinrer, D Dersaw, I Schreer, Thieme

/ Breast Imaging

CHAPTER OUTLINE:

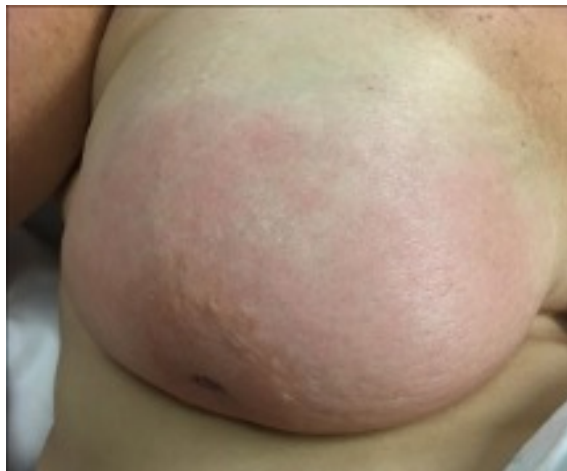- Breast Anatomy
- Anatomical Variants
- Pregnancy and Lactation
- Diagnostic Imaging Techniques
- Disease of the Breast: Benign

Disease of the Breast: Malignant

- / Malignant Diseases of the Breast

- Axilla
- Interventional Procedures
- Screening
- High Risk Women
- Communication
- Multidisciplinary Team Meeting
- Take-Home Messages
- References
- Test Your Knowledge

- / The most frequent type of carcinoma is **invasive ductal carcinoma (IDC)** Not Otherwise Specified (NOS) type (80%), followed by the invasive lobular carcinoma (about 15%) .
- / Special types of invasive ductal carcinomas are:
 - / Mucinous carcinoma (3%)
 - / Tubular carcinoma (2-3%)
 - / Medullary carcinoma (3-4%)
 - / Papillary carcinoma (2%).
- / Mucinous carcinoma and medullary carcinoma are sometimes well circumscribed.
- / Therefore, to differentiate from a fibroadenoma, core needle biopsy is indicated in case a new or growing lesion is detected.
- / Inflammatory breast cancer is a condition in which tumour cells are in the lymphatic skin vessels, responsible for the clinical presentation of oedema, erythema and hyperthermia.
- / Other rarer types of carcinoma include Paget's disease of the nipple, malignant phyllodes tumour and sarcoma of the breast.



Skin oedema, redness of the right breast, courtesy of Multidisciplinary Breast Center, University Hospitals Leuven, Belgium

<=> REFERENCE

Diagnostic breast imaging, SH Heywant-Köbrin-
ner, D Dersaw, I Schreer, Thieme

/ Breast Imaging

CHAPTER OUTLINE:

- Breast Anatomy
- Anatomical Variants
- Pregnancy and Lactation
- Diagnostic Imaging Techniques
- Disease of the Breast: Benign
- Disease of the Breast: Malignant**
 - / Malignant Diseases of the Breast

- Axilla
- Interventional Procedures
- Screening
- High Risk Women
- Communication
- Multidisciplinary Team Meeting
- Take-Home Messages
- References
- Test Your Knowledge

/ Axilla

/ Breast Imaging

CHAPTER OUTLINE:

Breast Anatomy

Anatomical Variants

Pregnancy and Lactation

Diagnostic Imaging
Techniques

Disease of the Breast:
Benign

Disease of the Breast:
Malignant

Axilla

Interventional Procedures

Screening

High Risk Women

Communication

Multidisciplinary Team
Meeting

Take-Home Messages

References

Test Your Knowledge

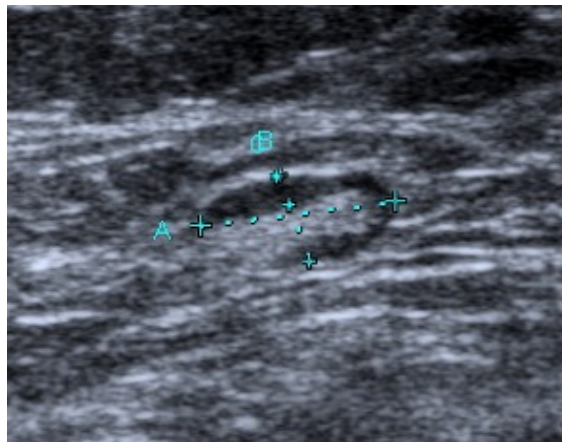
/ Background

<=> ATTENTION

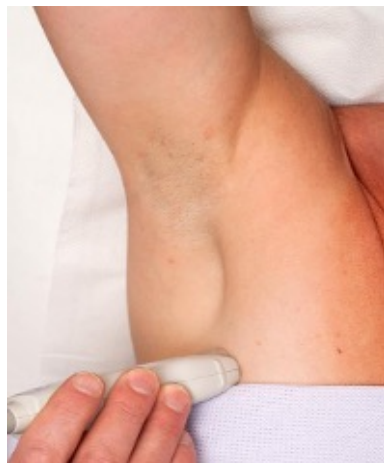The presence of axillary node metastasis remains one of most important prognostic factors in breast cancer.

Approximately 30-40% of newly diagnosed breast cancer patients will have nodal metastases.

It is routine practice to perform axillary ultrasound in all patients with suspected breast cancer on initial imaging.



Ultrasound appearances of a normal axillary lymph node



Axillary ultrasound being performed in a patient with suspected breast cancer. Note the abducted position of the arm

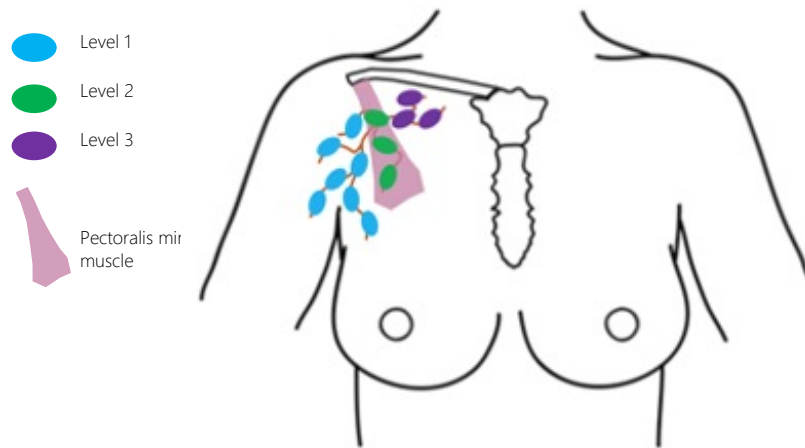
/ **Breast Imaging**

CHAPTER OUTLINE:

- Breast Anatomy
- Anatomical Variants
- Pregnancy and Lactation
- Diagnostic Imaging Techniques
- Disease of the Breast: Benign
- Disease of the Breast: Malignant
- Axilla**
- Interventional Procedures
- Screening
- High Risk Women
- Communication
- Multidisciplinary Team Meeting
- Take-Home Messages
- References
- Test Your Knowledge

/ Anatomy of the Axilla

- / Anatomically the axilla has a 3 dimensional shape resembling a pyramid, and contains structures including the axillary artery and vein, brachial plexus, and axillary lymph nodes.
- / The axilla is divided into three levels by the pectoralis minor muscle.
- / Drainage generally proceeds in a stepwise fashion from level I to II to III, and finally into the thorax.



Anatomy of axillary lymph node levels depending on location of the pectoralis minor muscle

<=> ATTENTION

Nodal metastases to level III carry a worse prognosis than metastases to level I and level II axillary nodes.

/ Breast Imaging

CHAPTER OUTLINE:

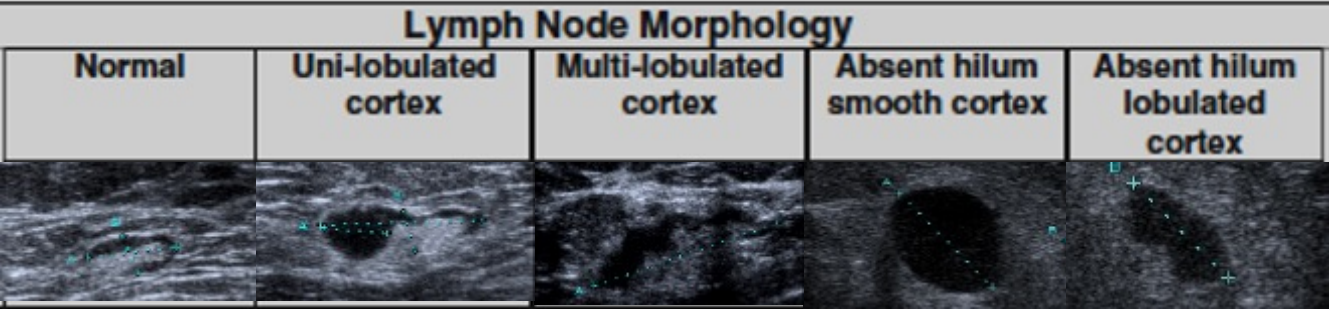
- Breast Anatomy
- Anatomical Variants
- Pregnancy and Lactation
- Diagnostic Imaging Techniques
- Disease of the Breast: Benign
- Disease of the Breast: Malignant
- Axilla**
 - / Anatomy
 - Interventional Procedures
 - Screening
 - High Risk Women
 - Communication
 - Multidisciplinary Team Meeting
 - Take-Home Messages
 - References
 - Test Your Knowledge

/ Appearances of Axillary Lymph Nodes on Ultrasound

The normal axillary lymph node should be oval with a smooth, well-defined margin and a uniformly thin hypoechoic cortex. The echogenic hilum should comprise most of the lymph node.

Cortical thickening or a focal cortical budge are considered the earliest detectable changes.

Replacement of the entire node by an ill-defined mass is highly suspicious for malignant involvement of nodes, however this finding is non-specific and is often associated with reactive nodes.



Appearances of normal and abnormal axillary lymph nodes on US .

/ Breast Imaging

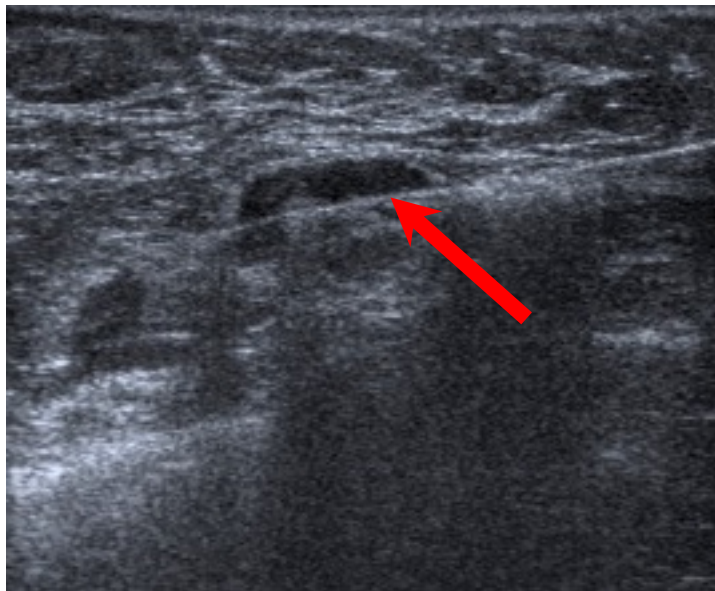
CHAPTER OUTLINE:

- Breast Anatomy
- Anatomical Variants
- Pregnancy and Lactation
- Diagnostic Imaging Techniques
- Disease of the Breast: Benign
- Disease of the Breast: Malignant
- Axilla**
 - / Appearance on Ultrasound
- Interventional Procedures
- Screening
- High Risk Women
- Communication
- Multidisciplinary Team Meeting
- Take-Home Messages
- References
- Test Your Knowledge

/ Intervention in the Axilla

<=> ATTENTION

If ultrasound evaluation of the axilla reveals a suspicious finding, percutaneous procedures including ultrasound guided fine needle aspiration (FNA) or ultrasound guided core needle biopsy (CNB) should be performed to substantiate clinical decision making.



Biopsy needle through a lymph node cortex.

/ Breast Imaging

CHAPTER OUTLINE:

- Breast Anatomy
- Anatomical Variants
- Pregnancy and Lactation
- Diagnostic Imaging Techniques
- Disease of the Breast: Benign
- Disease of the Breast: Malignant
- Axilla**
 - / Intervention
- Interventional Procedures
- Screening
- High Risk Women
- Communication
- Multidisciplinary Team Meeting
- Take-Home Messages
- References
- Test Your Knowledge

CHAPTER OUTLINE:

Breast Anatomy

Anatomical Variants

Pregnancy and Lactation

Diagnostic Imaging
Techniques

Disease of the Breast:
Benign

Disease of the Breast:
Malignant

Axilla

**Interventional
Procedures**

Screening

High Risk Women

Communication

Multidisciplinary Team
Meeting

Take-Home Messages

References

Test Your Knowledge

/ Interventional Procedures

/ Interventional Procedures

- / **Percutaneous image-guided needle biopsy** is part of the so called “diagnostic triad” in breast imaging together with mammography and ultrasound. It is essential in the management of suspicious breast lesions detected by screening or during assessment of clinical abnormalities. It is safe and cost effective, allowing accurate decision making, including treatment planning.
- / The most appropriate image guide is chosen by radiologist (whenever a lesion is seen on ultrasound, this technique is preferred!).

- / Different percutaneous image-guided techniques are available:

1. **Fine-Needle Aspiration Cytology (FNAC)** > providing material to study cells
2. **Core Needle Biopsy (CNB)** > providing material to study tissue
3. **Vacuum-Assisted Biopsy (VAB)**

- / Indications:

- / BI-RADS Category 4A: >2% but ≤10% likelihood of malignancy
- / BI-RADS Category 4B: >10% but ≤50% likelihood of malignancy
- / BI-RADS Category 4C: >50% but <95% likelihood of malignancy
- / BI-RADS Category 5 : >95% likelihood of malignancy

/ Breast Imaging

CHAPTER OUTLINE:

- Breast Anatomy
- Anatomical Variants
- Pregnancy and Lactation
- Diagnostic Imaging Techniques
- Disease of the Breast: Benign
- Disease of the Breast: Malignant
- Axilla
- Interventional Procedures**
- Screening
- High Risk Women
- Communication
- Multidisciplinary Team Meeting
- Take-Home Messages
- References
- Test Your Knowledge

/ Fine Needle Aspiration Cytology

Fine Needle Aspiration Cytology (FNAC) provides material for studying cells allowing a cytological examination

- / **Principle:** usually performed under US guidance with a **27-18 gauge** fine needle that is inserted very close to US probe. Once the needle is in the target, manual multidirectional sampling is performed, through aspiration using 10-20 ml syringe or simple by manual movement of the needle inside for about 10-20 sec. The extracted material is spread onto slides and fixed in formalin for analysis.

ADVANTAGES:

- + Easy, safe and fast procedure.
- + Cost and availability.

DISADVANTAGES:

- No histopathological analysis.
- High rates of inadequate or false negative results.

Indications:

- / Drainage of complicated cysts, seromas, hematomas.
- / For therapeutic purposes:
 - / pain relief from swelling cysts, therapy of lactational and non lactational breast abscesses.
- / Currently discouraged for diagnostic purposes for the lack of molecular information and inadequate rate.



>=< FURTHER KNOWLEDGE

False negative rate ranges up to 20%.

/ Breast Imaging

CHAPTER OUTLINE:

- Breast Anatomy
- Anatomical Variants
- Pregnancy and Lactation
- Diagnostic Imaging Techniques
- Disease of the Breast: Benign
- Disease of the Breast: Malignant
- Axilla
- Interventional Procedures**
 - / FNAC
- Screening
- High Risk Women
- Communication
- Multidisciplinary Team Meeting
- Take-Home Messages
- References
- Test Your Knowledge

/ Core Needle Biopsy

Core Needle Biopsy (CNB) provides material for histopathological analysis.

/ **Principle:** usually performed under US guidance with a needle from 16 to 12 gauge (recommended 14 gauge). Using an aseptic technique and after local anaesthesia administered through subcutaneous injections (lidocaine/mepivacaine) the needle is inserted, through a small skin incision. Once the needle is in the target a number of cores (3-5) are obtained to document the correct needle positioning. The extracted material is placed in formalin.

ADVANTAGES:

- + Easy, safe and fast procedure.
- + Cost and availability.

DISADVANTAGES:

- Subsequent samples imply needle extractions.
- False negative rate 1.2-3.3%.

Post interventional marker clip must be deployed in patients undergoing neoadjuvant treatment or upon radiologist indication.

Indications:

- / Suspicious (BI-RADS 4a,4b,4c-5) lesions seen at US.
- / Axillary lymph nodes assessment.



>=< FURTHER KNOWLEDGE

False negative rate ranges from 1.2 to 3.3% (mean 2%).

/ Breast Imaging

CHAPTER OUTLINE:

- Breast Anatomy
- Anatomical Variants
- Pregnancy and Lactation
- Diagnostic Imaging Techniques
- Disease of the Breast: Benign
- Disease of the Breast: Malignant
- Axilla
- Interventional Procedures**
 - / CNB
- Screening
- High Risk Women
- Communication
- Multidisciplinary Team Meeting
- Take-Home Messages
- References
- Test Your Knowledge

/ Vacuum-Assisted Biopsy

Vacuum-Assisted Biopsy (VAB) provides material for histopathological analysis.

/ **Principle:** performed with a needle from 12 to 7 gauge, after local anaesthesia under mammography/tomosynthesis/CEM, US and MRI guidance. A special needle connected to a vacuum-generating device is inserted, through a small skin incision. Once the needle is in the target the vacuum attracts the tissue towards the needle and a rotating device cuts the samples remaining in situ. Post interventional marker placement is encouraged.

ADVANTAGES:

- + Rapid removal of larger amount of tissue (1g).
- + Multiple samples without removing the needle.
- + Risk of lesion displacement reduced.

DISADVANTAGES:

- Moderate rate of complications.
- Cost and availability (MRI and CEM guidance).

Indications:

- / Suspicious microcalcifications or architectural tissue distortion on mammography/tomosynthesis.
- / Contrast-enhancing lesions on MRI, not visible with conventional imaging.
- / Radiologic-pathologic discordance after CNB.

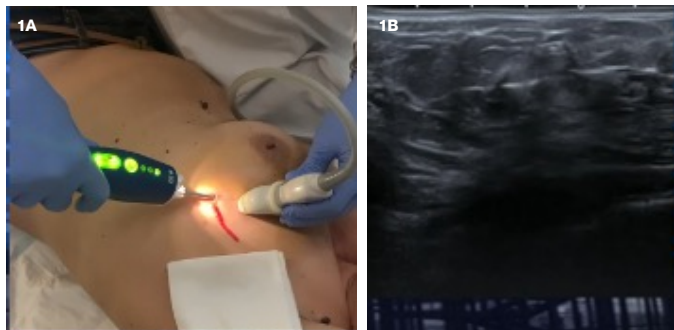
>=< FURTHER KNOWLEDGE

False negative rate ranges from 1.2 to 3.3% (mean 2%).

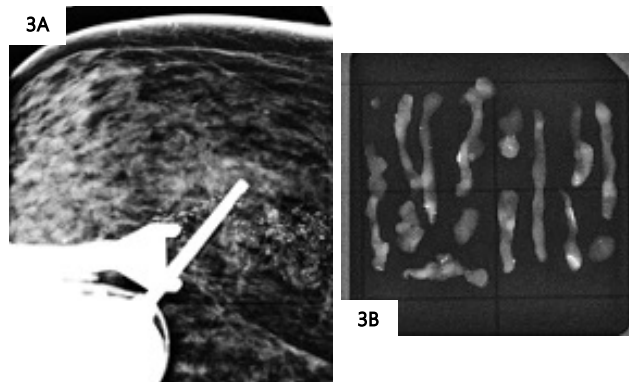
/ Breast Imaging

CHAPTER OUTLINE:

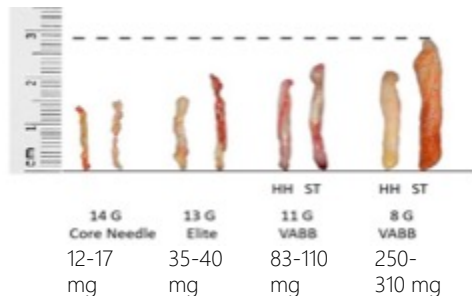
- Breast Anatomy
- Anatomical Variants
- Pregnancy and Lactation
- Diagnostic Imaging Techniques
- Disease of the Breast: Benign
- Disease of the Breast: Malignant
- Axilla
- Interventional Procedures**
 - / VAB
- Screening
- High Risk Women
- Communication
- Multidisciplinary Team Meeting
- Take-Home Messages
- References
- Test Your Knowledge



US-VABB. Ultrasound-guided vacuum assisted breast biopsy. The patient is in supine position. After local anesthesia the VABB device is inserted through the skin toward the target by means of US guidance (1A). The needle is working under the lesion and can take multiple samples without being removed from the breast (1B).



Tomosynthesis-VABB. The patient is in prone position on the dedicated horizontal table. The location of the lesion is calculated through the system and the needle is automatically brought to the exact position (3A, post-fire 2D image). Radiography of the specimens shows the presence of microcalcifications and confirms the adequate sampling (3B). Histological examination revealed a poorly differentiated G3 in situ ductal carcinoma.



Average weight and size of biopsy samples obtained with different needle gauges. (Adapted from La Forgia et al, Diagnostics, 2020).

<=> ATTENTION

The most important step to avoid false negative results is systematic radiologic-pathologic correlation.

Breast Imaging

CHAPTER OUTLINE:

- Breast Anatomy
- Anatomical Variants
- Pregnancy and Lactation
- Diagnostic Imaging Techniques
- Disease of the Breast: Benign
- Disease of the Breast: Malignant
- Axilla
- Interventional Procedures**
- / VAB
- Screening
- High Risk Women
- Communication
- Multidisciplinary Team Meeting
- Take-Home Messages
- References
- Test Your Knowledge

/ Vacuum-Assisted Excision

Vacuum-Assisted Excision (VAE) provides material for histopathological analysis

- / Technique: VABB devices with a collection of approximately 4 g of tissue (12-18 x 7 Gauge cores)

Indications:

- / B3 lesions found at first-attempt diagnostic VAB.
- / The practice across Europe and UK regarding the role of VAE in managing B3 lesions remains variable.
- / In 2016, the first international guidelines from Europe were published regarding the management of B3 lesions, and this was recently updated in 2019. For details refer to these documents.

ADVANTAGES:

- + Reduced surgery.
- + Reduced hospitalisation and cost.
- + Better cosmetic results.
- + Reduced risk of complications.

DISADVANTAGES:

- Underestimation of malignancy in excised B3 lesions ranges from about 10 to 35%.

/ Breast Imaging

CHAPTER OUTLINE:

- Breast Anatomy
- Anatomical Variants
- Pregnancy and Lactation
- Diagnostic Imaging Techniques
- Disease of the Breast: Benign
- Disease of the Breast: Malignant
- Axilla
- Interventional Procedures**
 - / VAE
- Screening
- High Risk Women
- Communication
- Multidisciplinary Team Meeting
- Take-Home Messages
- References
- Test Your Knowledge

/ Pre-Operative Image-Guided Localisation

Non palpable breast lesions need image-guided preoperative localisation, allowing for a safe and effective complete removal (clear margins) and cosmetic result. There is no clear evidence to support one guided technique over another with similar feasibility rate. Local policies and resources guide the choice.

>=< FURTHER KNOWLEDGE

Current options

/ Carbon marking

Long standing methods. Surgery up to 1 month after.

/ Wire localisation

Most commonly used method

Safe and cost effective. Surgery within 24 h after. Possible rupture/migration.

/ Radio-guided localisation

Surgery within 24 h after. Radiation exposure. Higher cost and complex logistics.

/ Radioactive seed localisation

Longer interval time admitted between procedure and surgery. Radiation exposure. Higher cost.

/ Magnetic seed localisation

Surgery up to 1 month after. Higher cost. Artefact in Breast MRI.

/ Breast Imaging

CHAPTER OUTLINE:

Breast Anatomy

Anatomical Variants

Pregnancy and Lactation

Diagnostic Imaging Techniques

Disease of the Breast: Benign

Disease of the Breast: Malignant

Axilla

Interventional Procedures

/ Pre-Operative Localisation

Screening

High Risk Women

Communication

Multidisciplinary Team Meeting

Take-Home Messages

References

Test Your Knowledge

/ Minimal Invasive Therapy: a Goal for the Future

These treatments can achieve local tumour ablation through various types of energy that destroy tumour cells in different ways

/ Radiofrequency	>	Electromagnetic waves
/ Microwaves		
/ Laser ablation		
/ Cryoablation	>	Cooling
/ High-intensity focus ultrasound (HIFU)		
	>	Mechanical waves

Indications:

- / B3 lesions found at first-attempt diagnostic VAB.
- / The practice across Europe and UK regarding the role of VAE in managing B3 lesions remains variable.
- / In 2016, the first international guidelines from Europe were published regarding the management of B3.

POTENTIAL ADVANTAGES:

- + Local anaesthesia.
- + Reduced hospitalisation and cost.
- + Better cosmetic results.
- + Reduced risk of complications.

LIMITATIONS:

- Lack of pathological examination of the entire lesion.
- Large/multicentric tumours.
- Tumours close to skin/muscle.

/ Breast Imaging

CHAPTER OUTLINE:

- Breast Anatomy
- Anatomical Variants
- Pregnancy and Lactation
- Diagnostic Imaging Techniques
- Disease of the Breast: Benign
- Disease of the Breast: Malignant
- Axilla
- Interventional Procedures**
 - / Minimal Invasive Therapy
- Screening
- High Risk Women
- Communication
- Multidisciplinary Team Meeting
- Take-Home Messages
- References
- Test Your Knowledge

/ Breast Imaging

CHAPTER OUTLINE:

- Breast Anatomy
- Anatomical Variants
- Pregnancy and Lactation
- Diagnostic Imaging Techniques
- Disease of the Breast: Benign
- Disease of the Breast: Malignant
- Axilla
- Interventional Procedures
- Screening**
- High Risk Women
- Communication
- Multidisciplinary Team Meeting
- Take-Home Messages
- References
- Test Your Knowledge

/ Screening

/ Why screen? - The Basics

<=> ATTENTION

- / **Early cancer detection** increases the probability of **successful treatment**.
- / The **aim of breast cancer screening** programmes is to reduce breast cancer mortality by early detection and early treatment of asymptomatic cancer.
- / **Screening mammography in national screening programmes** includes mammography performed every 1, 2 or 3 years from the age of 40–50 years until around 70–75.

<=> ATTENTION

- / **European guidelines** suggest the 2-year interval for the general female population from 50 to 70 years of age & every 2 or 3 years for women aged 45 to 49 years.

/ Breast Imaging

CHAPTER OUTLINE:

- Breast Anatomy
- Anatomical Variants
- Pregnancy and Lactation
- Diagnostic Imaging Techniques
- Disease of the Breast: Benign
- Disease of the Breast: Malignant
- Axilla
- Interventional Procedures
- Screening**
- High Risk Women
- Communication
- Multidisciplinary Team Meeting
- Take-Home Messages
- References
- Test Your Knowledge

/ Wilson & Junger Outlined 10 Criteria for Screening

1. The condition screened for should be an IMPORTANT one
2. There should be an ACCEPTABLE TREATMENT for the disease
3. DIAGNOSTIC & TREATMENT facilities should be available
4. A RECOGNISABLE LATENT or EARLY SYMPTOMATIC stage is required
5. There should be an AGREED POLICY on who to treat
6. The test must be of HIGH DISCRIMINATORY POWER, VALID (measuring what it proposes to measure) & be REPRODUCIBLE
7. The test must be ACCEPTABLE to the client being screened
8. The NATURAL HISTORY of the untreated disease should be adequately understood
9. The COST of case-finding (diagnosing and treating patients diagnosed) should be economically balanced in relation to possible expenditure on medical care as a whole
10. Screening is a CONTINUOUS PROCESS

/ Breast Imaging

CHAPTER OUTLINE:

- Breast Anatomy
- Anatomical Variants
- Pregnancy and Lactation
- Diagnostic Imaging Techniques
- Disease of the Breast: Benign
- Disease of the Breast: Malignant
- Axilla
- Interventional Procedures
- Screening**
- High Risk Women
- Communication
- Multidisciplinary Team Meeting
- Take-Home Messages
- References
- Test Your Knowledge

/ Risk Factors

A **risk factor** is defined as anything that affects an individual's chance of getting a disease.



Certain major risk factors for breast cancer are beyond an individual's control.



Simply **being a woman** is the main risk factor for breast cancer.
Breast cancer is about 100 times more likely to occur in women than in men.



Aging inevitably increases the risk of developing breast cancer. Almost 8 out of 10 women diagnosed are over the age of 50. Breast cancer is rare in women under 30 years old.

/ Breast Imaging

CHAPTER OUTLINE:

- Breast Anatomy
- Anatomical Variants
- Pregnancy and Lactation
- Diagnostic Imaging Techniques
- Disease of the Breast: Benign
- Disease of the Breast: Malignant
- Axilla
- Interventional Procedures
- Screening**
 - / Risk Factors
 - High Risk Women
 - Communication
 - Multidisciplinary Team Meeting
 - Take-Home Messages
 - References
 - Test Your Knowledge

/ Factors Associated with an Increased Risk of Breast Cancer

- / Family history.
- / Early menarche (age < 12 years).
- / Late first pregnancy (after age 28 years).
- / Current use of an Oral Contraceptives Pill (OCP) and for 10 years later Nulliparity.
- / Late menopause.
- / Prolonged use of Hormone Replacement Therapy (HRT).
- / Significant weight gain in adult life.
- / Sedentary lifestyle.
- / Increased mammographic breast density.

/ Breast Imaging

CHAPTER OUTLINE:

- Breast Anatomy
- Anatomical Variants
- Pregnancy and Lactation
- Diagnostic Imaging Techniques
- Disease of the Breast: Benign
- Disease of the Breast: Malignant
- Axilla
- Interventional Procedures
- Screening**
 - / Risk Factors
- High Risk Women
- Communication
- Multidisciplinary Team Meeting
- Take-Home Messages
- References
- Test Your Knowledge

/ Age & Risk of Breast Cancer

Risk up to and including age 29 years	1 in 2000
Risk up to and including age 39 years	1 in 315
Risk up to and including age 49 years	1 in 50
Risk up to and including age 59 years	1 in 22
Risk up to and including age 69 years	1 in 13
Lifetime Risk	1 in 8

/ Breast Imaging

CHAPTER OUTLINE:

- Breast Anatomy
- Anatomical Variants
- Pregnancy and Lactation
- Diagnostic Imaging Techniques
- Disease of the Breast: Benign
- Disease of the Breast: Malignant
- Axilla
- Interventional Procedures
- Screening**
 - / Risk Factors
- High Risk Women
- Communication
- Multidisciplinary Team Meeting
- Take-Home Messages
- References
- Test Your Knowledge

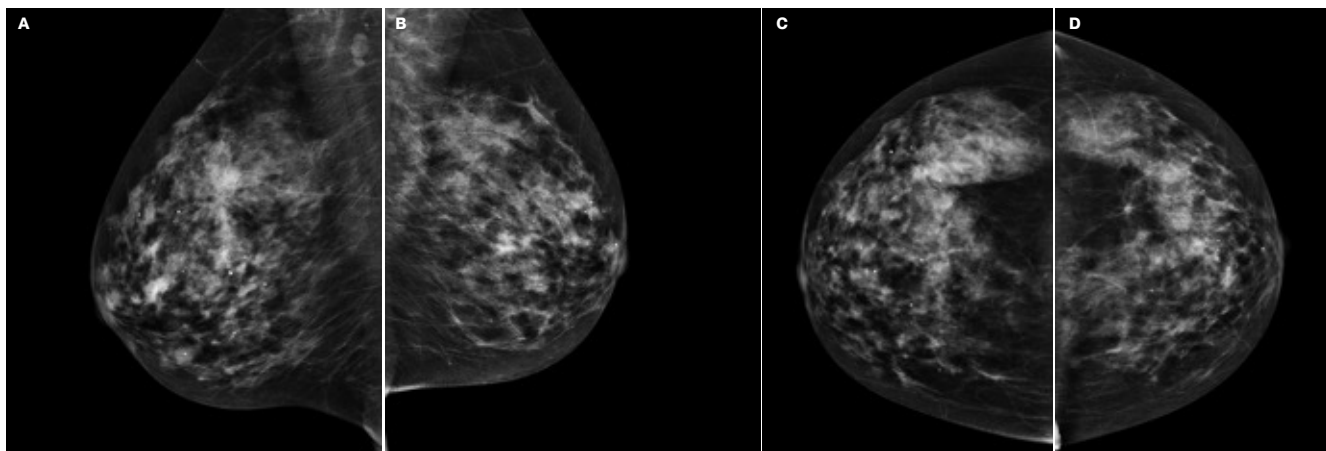
/ How to Screen?

Screening test:

THE MAMMOGRAM (direct digital acquisition)

<=> ATTENTION

Studies show that even when women have access to the latest therapies deaths from breast cancer decline at a much higher rate than women who get mammographic screening.



4 VIEWS: Right & Left Mediolateral oblique views (a,b) AND Bilateral Craniocaudal views (c,d). Breast compressed between paddles.

/ Breast Imaging

CHAPTER OUTLINE:

- Breast Anatomy
- Anatomical Variants
- Pregnancy and Lactation
- Diagnostic Imaging Techniques
- Disease of the Breast: Benign
- Disease of the Breast: Malignant
- Axilla
- Interventional Procedures
- Screening**
 - / How to Screen
 - High Risk Women
 - Communication
 - Multidisciplinary Team Meeting
 - Take-Home Messages
- References
- Test Your Knowledge

/ Limitations of Breast Screening

<=> ATTENTION

/ Breast Imaging

CHAPTER OUTLINE:

Breast Anatomy

Anatomical Variants

Pregnancy and Lactation

Diagnostic Imaging
TechniquesDisease of the Breast:
BenignDisease of the Breast:
Malignant

Axilla

Interventional Procedures

Screening

/ Limitations of Screening

High Risk Women

Communication

Multidisciplinary Team
Meeting

Take-Home Messages

References

Test Your Knowledge

Interval cancer and false positive recalls

- / Cancer may still develop in between one screening round and the next. Any symptoms which develop in the interim should not be dismissed without work-up.
- / A number of screening clients may undergo additional tests (additional mammo views, ultrasonography with or without needle sampling) - and associated worry - which result in a benign diagnosis. The average risk of false positive recall of clients undergoing biennial screening aged 50-69 years has been calculated at 20%.

“Overdiagnosis”

- / Some screen-detected breast cancers would have never otherwise been found and would not have become life-threatening. There is as yet no way to identify which breast cancers are not life-threatening and treatment is offered for all diagnosed breast cancers.

CHAPTER OUTLINE:

Breast Anatomy

Anatomical Variants

Pregnancy and Lactation

Diagnostic Imaging
TechniquesDisease of the Breast:
BenignDisease of the Breast:
Malignant

Axilla

Interventional Procedures

Screening

/ Limitations of Screening

High Risk Women

Communication

Multidisciplinary Team
Meeting

Take-Home Messages

References

Test Your Knowledge

Radiation penalty

- / Mammography involves exposure of the breast tissue to ionising radiation (which is potentially carcinogenic).
- / The effective dose for standard 2-view mammogram of each breast is 0.4mSV for digital mammography. (This may be comparable to 2 months of background radiation quoted at 3mSV per annum or the equivalent of under a third of the effective dose from a lumbosacral spine radiograph).
- / The small risk of radiation-induced cancer in an organised and controlled breast screening programme is outweighed by the benefits of expected mortality reduction.

"Mammography of Dense Breast"

- / Breast density is the measure of the proportion of glandular tissue Vs fatty tissue in a breast on mammography. The similar x-ray absorption of fibroglandular tissue and breast cancers results in potential masking of breast cancers on mammography in denser breasts.

CHAPTER OUTLINE:

Breast Anatomy

Anatomical Variants

Pregnancy and Lactation

Diagnostic Imaging
Techniques

Disease of the Breast:
Benign

Disease of the Breast:
Malignant

Axilla

Interventional Procedures

Screening

High Risk Women

Communication

Multidisciplinary Team
Meeting

Take-Home Messages

References

Test Your Knowledge

/ High Risk Women

/ Introduction

<=> ATTENTION

- / All national breast cancer screening programs offer the same imaging to every eligible woman except where there is evidence of increased risk factors for developing breast cancer.
- / Risk for breast cancer is calculated based on age, genetic testing, family history of breast and ovarian cancer, and clinical history (personal history of breast cancer, chest radiation, history of a breast biopsy with atypical epithelial proliferations in the breast, and extremely dense breasts).
- / Women can be classified as being at average, intermediate and high lifetime risk of developing breast cancer.
- / Women at **average risk** are considered those with a lifetime risk developing breast cancer of < 15%.
- / Women at **intermediate risk** are considered those with a lifetime risk developing breast cancer ranged between 15% and 20%, a personal history of breast cancer, dense breasts at mammography or a history of high-risk lesions at biopsy (specifically, atypical ductal hyperplasia, atypical lobular hyperplasia, and lobular carcinoma in situ).
- / Women at **high risk** are considered those with a lifetime risk developing breast cancer of > 20%.

/ Breast Imaging

CHAPTER OUTLINE:

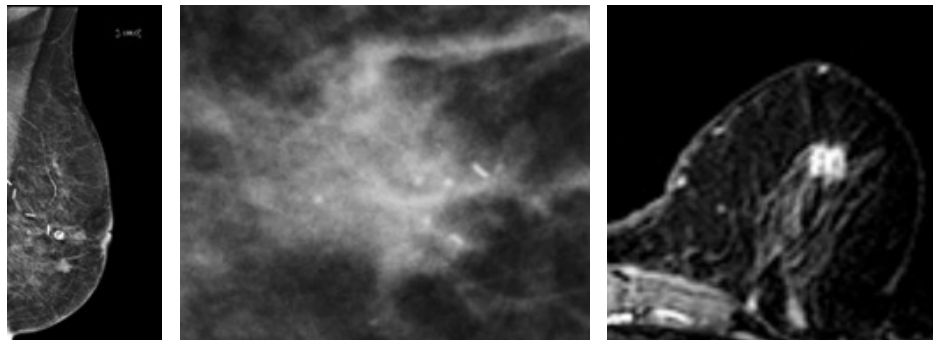
Breast Anatomy
Anatomical Variants
Pregnancy and Lactation
Diagnostic Imaging Techniques
Disease of the Breast: Benign
Disease of the Breast: Malignant
Axilla
Interventional Procedures
Screening
High Risk Women
/ Introduction
Communication
Multidisciplinary Team Meeting
Take-Home Messages
References
Test Your Knowledge

/ Personal History of Breast Cancer: Screening

<=> ATTENTION

Women with a personal history of breast cancer are at a substantially increased risk for the development of a recurrence or second breast cancer.

The sensitivity of mammography for early detection of second breast cancers is slightly reduced due to postoperative changes, including scar formation and dystrophic calcifications.



/ Annual breast MRI as an adjunct to mammography for women with a previous breast cancer diagnosis at an age younger than 50 years is now recommended in the USA.

/ Breast Imaging

CHAPTER OUTLINE:

- Breast Anatomy
- Anatomical Variants
- Pregnancy and Lactation
- Diagnostic Imaging Techniques
- Disease of the Breast: Benign
- Disease of the Breast: Malignant
- Axilla
- Interventional Procedures
- Screening
- High Risk Women**
 - / History
- Communication
- Multidisciplinary Team Meeting
- Take-Home Messages
- References
- Test Your Knowledge

/ History of Atypical Epithelial Proliferations in the Breast

Women with history of atypical epithelial proliferation such as atypical ductal hyperplasia (ADH), atypical lobular hyperplasia (ALH), and lobular carcinoma in situ (LCIS) have a relative risk of 3 to 10 times higher of developing breast cancer compared with the general population.

/ If left in the breast, these lesions might develop into a ductal carcinoma in situ (DCIS) or invasive carcinoma although the progression to malignancy is low and occurs over a long period (PPV 10-15%);

/ The risk to develop breast cancer in the same or contralateral breast is respectively 3.8% to 3.7% at 10 years, 8.9% to 8.6% at 15 years and 30.5% to 26.2% at 25 years from the diagnosis.

/ Breast Imaging

CHAPTER OUTLINE:

Breast Anatomy

Anatomical Variants

Pregnancy and Lactation

Diagnostic Imaging
Techniques

Disease of the Breast:
Benign

Disease of the Breast:
Malignant

Axilla

Interventional Procedures

Screening

High Risk Women

/ History

Communication

Multidisciplinary Team
Meeting

Take-Home Messages

References

Test Your Knowledge

HIGH RISK LESION

IMAGING FINDINGS

Atypical Ductal Hyperplasia (ADH)

Fine pleomorphic microcalcifications and linear or segmental distribution.
As an irregular-shaped small hypoechoic mass with micro-lobulated edges.

Lobular Neoplasia (LN)

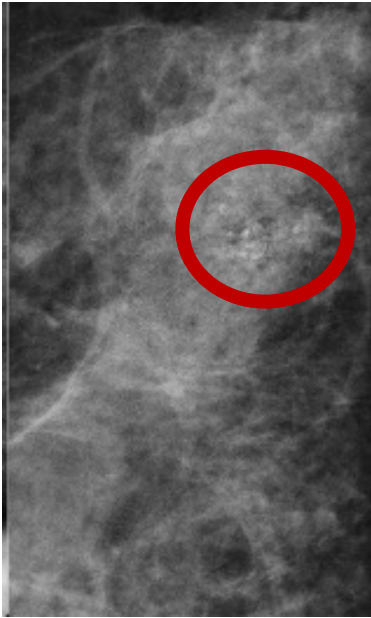
Amorphous microcalcifications and grouped distribution.

<!> ATTENTION

Currently, annual screening mammography with consideration for annual MRI in women with history of atypia, especially if other risk factors are present is indicated.

Modified from Catanzariti F. et al (2021)

Atypical Ductal Hyperplasia (ADH)



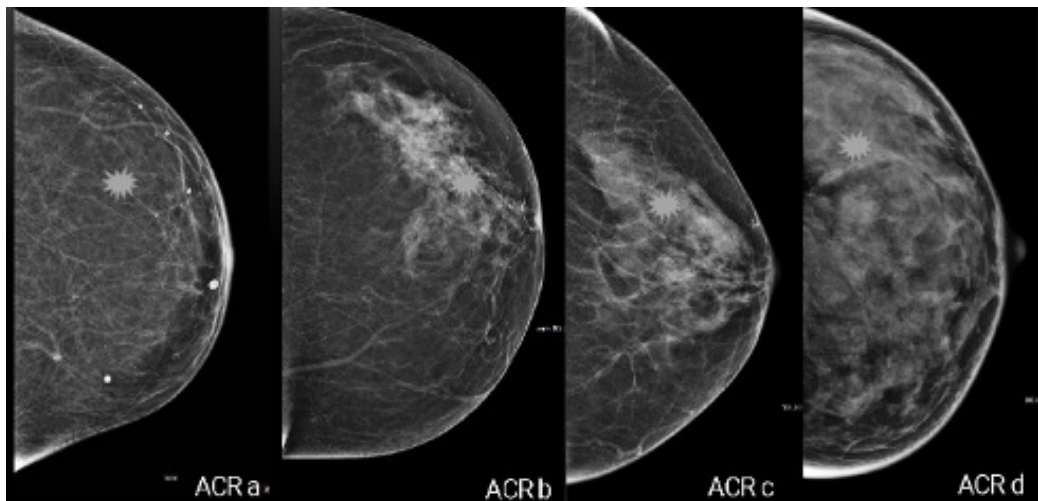
Breast Imaging

CHAPTER OUTLINE:

- Breast Anatomy
- Anatomical Variants
- Pregnancy and Lactation
- Diagnostic Imaging Techniques
- Disease of the Breast: Benign
- Disease of the Breast: Malignant
- Axilla
- Interventional Procedures
- Screening
- High Risk Women
 - History
- Communication
- Multidisciplinary Team Meeting
- Take-Home Messages
- References
- Test Your Knowledge

/ Extremely Dense Breast: Masking Effect

The fibro-glandular tissue, commonly referred as “dense tissue”, absorbs ionising radiation and projects white on mammography like most cancers that appear white on mammography.



<=> ATTENTION

Cancers could therefore be hidden by dense (white) tissue.

This means that dense tissue may prevent - “mask” - the detection on mammography.

This is the so called “**masking effect**”.

/ Breast Imaging

CHAPTER OUTLINE:

Breast Anatomy

Anatomical Variants

Pregnancy and Lactation

Diagnostic Imaging Techniques

Disease of the Breast: Benign

Disease of the Breast: Malignant

Axilla

Interventional Procedures

Screening

High Risk Women

/ Density

Communication

Multidisciplinary Team Meeting

Take-Home Messages

References

Test Your Knowledge

/ Extremely Dense Breast: Independent Risk Factor

<!=> ATTENTION

Besides the risk of masking breast cancer, breast density is also one of the strongest known **independent risk factor** for developing breast cancer.

- / Dense breast tissue is common in women, with 31%-43% of the general screening population having heterogeneously dense (c) or extremely dense breasts (d) on mammography.
- / This is due to both the absolute higher amount of fibro-glandular tissue within the breast and the breast composition.
- / Women with extremely dense breast (d) had a 4.6-fold increased breast cancer risk (95% confidence interval, 3.6-5.9) compared with women with fatty breasts.

/ Breast Imaging

CHAPTER OUTLINE:

- Breast Anatomy
- Anatomical Variants
- Pregnancy and Lactation
- Diagnostic Imaging Techniques
- Disease of the Breast: Benign
- Disease of the Breast: Malignant
- Axilla
- Interventional Procedures
- Screening
- High Risk Women**
 - / Density
- Communication
- Multidisciplinary Team Meeting
- Take-Home Messages
- References
- Test Your Knowledge

/ Extremely Dense Breast: Screening

<!=> ATTENTION

In women with extremely dense breast tissue the sensitivity of digital mammography (DM) screening is about 62–68% compared to 86 to 89% in women with fatty breasts.

The use of digital breast tomosynthesis (DBT) has increased the cancer detection rates by 20 to 40% in women with dense breasts.

However, both DM and DBT seem to be heavily affected by breast density and thus lead to underdiagnosis of relevant cancers in these women.

The added value of supplemental ultrasound regarding cancer detection is limited, especially concerning the high number of false positive examinations.

/ Breast Imaging

CHAPTER OUTLINE:

Breast Anatomy

Anatomical Variants

Pregnancy and Lactation

Diagnostic Imaging
Techniques

Disease of the Breast:
Benign

Disease of the Breast:
Malignant

Axilla

Interventional Procedures

Screening

High Risk Women

/ Density

Communication

Multidisciplinary Team
Meeting

Take-Home Messages

References

Test Your Knowledge

<=> ATTENTION

/ **Breast
Imaging****CHAPTER OUTLINE:**

Breast Anatomy

Anatomical Variants

Pregnancy and Lactation

Diagnostic Imaging
TechniquesDisease of the Breast:
BenignDisease of the Breast:
Malignant

Axilla

Interventional Procedures

Screening

High Risk Women

/ Density

Communication

Multidisciplinary Team
Meeting

Take-Home Messages

References

Test Your Knowledge

The European Society of Breast Imaging (ESOBi) now recommends:

- / Women with extremely dense breasts should be appropriately informed about their density and on the diagnostic and prognostic implication of having dense breasts
- / Supplemental screening with breast MRI or breast MRI alone should be offered to women with extremely dense breast from age 50 to 70 years should preferably every 2 to 3 years
- / Supplemental ultrasound to mammography should be offered to women with dense breasts as an alternative to breast MRI when the MRI screening is not available

/ High Risk Women

High-Risk are women with a lifetime risk equal to or higher than 20% of developing breast cancer in their life.

This includes women with:

- / Hereditary breast cancer
- / Familial Risk of breast and ovarian cancer
- / History of chest wall radiation at a young age

/ Breast Imaging

CHAPTER OUTLINE:

Breast Anatomy

Anatomical Variants

Pregnancy and Lactation

Diagnostic Imaging
Techniques

Disease of the Breast:
Benign

Disease of the Breast:
Malignant

Axilla

Interventional Procedures

Screening

High Risk Women

/ High Risk

Communication

Multidisciplinary Team
Meeting

Take-Home Messages

References

Test Your Knowledge

/ Hereditary Breast Cancer

- / Women diagnosed with breast cancers are carriers of a known genetic mutation in about 5-10% of cases.
- / The presence of a BRCA1 or BRCA2 mutation accounts for the majority of hereditary breast and ovarian cancer syndromes.
- / Other rarer gene mutations include TP53, PTEN, PALB2, STK11, CDH1, ATM, and CHECK2.
- / More than 2000 different mutations have been identified in BRCA1/2 genes, and in some populations—for example in Ashkenazi Jewish- the prevalence of a BRCA 1 or BRCA2 mutation is higher.



/ Breast Imaging

CHAPTER OUTLINE:

- Breast Anatomy
- Anatomical Variants
- Pregnancy and Lactation
- Diagnostic Imaging Techniques
- Disease of the Breast: Benign
- Disease of the Breast: Malignant
- Axilla
- Interventional Procedures
- Screening
- High Risk Women**
 - / High Risk
- Communication
- Multidisciplinary Team Meeting
- Take-Home Messages
- References
- Test Your Knowledge

/ Hereditary and Familial Risk

Women diagnosed with a genetic mutation carry a breast cancer risk that is different for each mutation:

- / For BRCA1 75–82%
- / For BRCA2 76–82%
- / For TP53 95% by 90 years old
- / For PTEN 85% by 80 years old
- / For CDH1 53% by 80 years old
- / For STK11 32% by 60 years old

Among men harbouring a BRCA1 or BRCA2 mutation, there is an estimated lifetime risk of breast cancer of 1.2% to $\leq 8\%$, respectively and a doubling of prostate cancer risk.

/ Breast Imaging

CHAPTER OUTLINE:

- Breast Anatomy
- Anatomical Variants
- Pregnancy and Lactation
- Diagnostic Imaging Techniques
- Disease of the Breast: Benign
- Disease of the Breast: Malignant
- Axilla
- Interventional Procedures
- Screening
- High Risk Women**
 - / High Risk
- Communication
- Multidisciplinary Team Meeting
- Take-Home Messages
- References
- Test Your Knowledge

/ Familial Risk of Breast and Ovarian Cancer

Patients with the following family histories of cancer, all on the same side of the family, are at increased risk and should be referred to Clinical Genetics:

- / Three or more 1st or 2nd degree relatives with breast and / or ovarian cancer
- / One 1st and one 1st or 2nd degree relative both with breast cancer or one with breast cancer and one with ovarian cancer
- / Two 1st or 2nd degree relatives with ovarian cancer or one 1st or 2nd degree relative with breast cancer and one 1st or 2nd degree relative with either a sarcoma < 45, a glioma or a childhood adrenal cortical carcinoma
- / A 1st degree relative with breast cancer under 40, or triple negative breast cancer under 60
- / A 1st degree relative with bilateral breast cancer or with male breast cancer or with both breast and ovarian cancer
- / Ashkenazi Jewish heritage with a 1st degree relative with breast cancer or ovarian cancer at any age

In the absence of a genetic mutation, the risk for women with a strong family history of breast cancer remains high, although somewhat lower compared to the one in whom a germline mutation is found.

/ Breast Imaging

CHAPTER OUTLINE:

Breast Anatomy

Anatomical Variants

Pregnancy and Lactation

Diagnostic Imaging Techniques

Disease of the Breast: Benign

Disease of the Breast: Malignant

Axilla

Interventional Procedures

Screening

High Risk Women

/ High Risk

Communication

Multidisciplinary Team Meeting

Take-Home Messages

References

Test Your Knowledge

/ High Risk Women: Screening

<=> ATTENTION

- / For high-risk women, national and international guidelines are in favour of including dedicated pathways for screening, offering breast magnetic resonance imaging (MRI).
- / International guidelines recommend screening high-risk women with yearly MRI from age 25 years onwards, and additional mammography from age 30 years.
- / Due to the high tumour growth rate and shorter lead time of BRCA-related breast cancers, alternating MR imaging and mammographic screening examinations at 6-month intervals also may be a clinically effective approach.
- / BRCA1/BRCA2 can choose between prophylactic bilateral mastectomy and ovariectomy, leading to a 90% risk reduction. Alternatively, they join screening programs.

/ Breast Imaging

CHAPTER OUTLINE:

Breast Anatomy

Anatomical Variants

Pregnancy and Lactation

Diagnostic Imaging
TechniquesDisease of the Breast:
BenignDisease of the Breast:
Malignant

Axilla

Interventional Procedures

Screening

High Risk Women

/ High Risk

Communication

Multidisciplinary Team
Meeting

Take-Home Messages

References

Test Your Knowledge

/ History of Chest Wall Radiation at a Young Age

- / There is a substantially increased risk of breast cancer following chest irradiation and breast cancer in women is the leading cause of death in long-term survivors of Hodgkin lymphoma.
- / Estimates of breast cancer are highest among women treated before the age of 30 years, due to the known sensitivity of breast tissue to radiation at younger ages.
- / The cumulative risk increases with the radiation dose delivered, volume of the radiation field, and time interval since completion of the radiation therapy.
- / The incidence of breast cancer increases after approximately 8 years following chest irradiation, and by the age of 40–45 years, 13%–20% of women treated with moderate- to high-dose chest irradiation for a paediatric cancer will be diagnosed with breast cancer.

<=> ATTENTION

Screening

- / Females irradiated below the age of 10 years- additional screening is not applicable to these females.
- / Females irradiated between ages of 10 and 19 are eligible for MRI screening annually from age 20 to < 71 years old. Surveillance starts at 25 or 8 years after first irradiation;
- / Females irradiated between ages of 20 and 29 are eligible for MRI screening annually from age 30 to 39 years, and from age 40 to < 71 annual MRI and mammographic screening;

/ Breast Imaging

CHAPTER OUTLINE:

- Breast Anatomy
- Anatomical Variants
- Pregnancy and Lactation
- Diagnostic Imaging Techniques
- Disease of the Breast: Benign
- Disease of the Breast: Malignant
- Axilla
- Interventional Procedures
- Screening
- High Risk Women**
 - / High Risk
- Communication
- Multidisciplinary Team Meeting
- Take-Home Messages
- References
- Test Your Knowledge

**Breast
Imaging**

CHAPTER OUTLINE:

Breast Anatomy

Anatomical Variants

Pregnancy and Lactation

Diagnostic Imaging
Techniques

Disease of the Breast:
Benign

Disease of the Breast:
Malignant

Axilla

Interventional Procedures

Screening

High Risk Women

Communication

Multidisciplinary Team
Meeting

Take-Home Messages

References

Test Your Knowledge

/ Communi- cation

/ Communication and Attendance to Screening

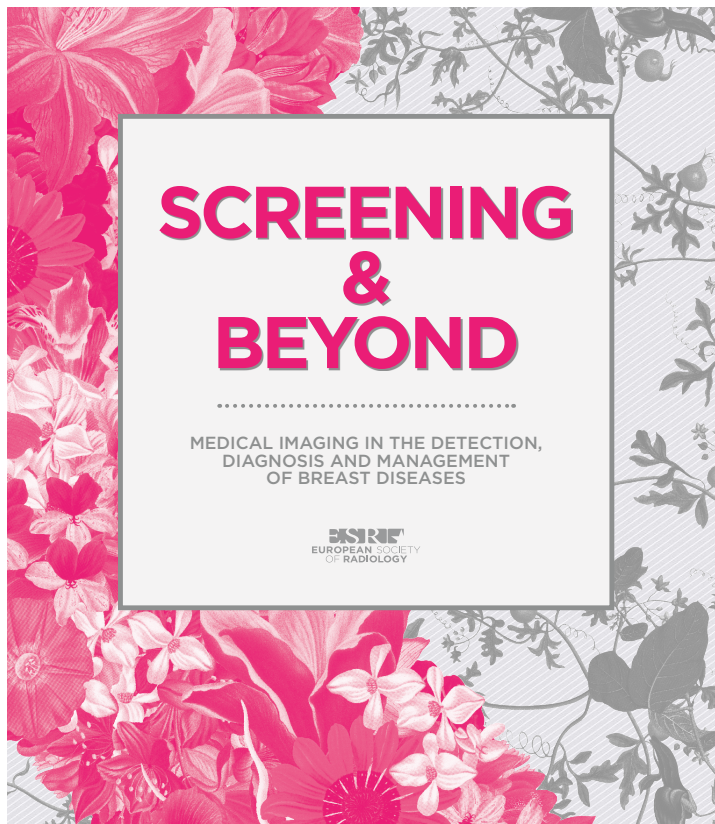
As breast imaging has become an important subspecialty of radiology, it has evolved into a more clinically oriented discipline.

There is far greater need for direct contact and communication with the patient about procedures, diagnoses, management options and follow-up recommendations.

There is now a greater emphasis on the need to understand the potential influences of communication to encourage ongoing participation in screening mammography.

<=> ATTENTION

In symptomatic patients > 40 years of age – mammographic assessment may be considered the first-line modality for breast assessment.



/ Breast Imaging

CHAPTER OUTLINE:

- Breast Anatomy
- Anatomical Variants
- Pregnancy and Lactation
- Diagnostic Imaging Techniques
- Disease of the Breast: Benign
- Disease of the Breast: Malignant
- Axilla
- Interventional Procedures
- Screening
- High Risk Women
- Communication**
 - / Mammography – Indications and Recommendations
- Multidisciplinary Team Meeting
- Take-Home Messages
- References
- Test Your Knowledge

/ What should be considered prior to booking a Mammogram appointment?

Premenopause

The correct time to schedule an appointment is day 7-12 of menstrual cycle.

Mammographic sensitivity is NOT limited by menstrual cycle – but tolerance of mammographic compression may be increased. Symptomatic patients may consider waiting for their period to see if symptoms are cycle related and may resolve.

Mammography is not performed in pregnancy and lactation.

Postmenopausal

No scheduling limitations save for consideration of interim since previous mammographic work-up.

If available, patient should take any previous breast imaging copies and reports for comparison.

/ Breast Imaging

CHAPTER OUTLINE:

Breast Anatomy

Anatomical Variants

Pregnancy and Lactation

Diagnostic Imaging Techniques

Disease of the Breast: Benign

Disease of the Breast: Malignant

Axilla

Interventional Procedures

Screening

High Risk Women

Communication

/ Mammography – Indications and Recommendations

Multidisciplinary Team Meeting

Take-Home Messages

References

Test Your Knowledge

/ Can a cancer be missed on Mammography?

Mammography is not a perfect test.

Up to 28% of cancers can be missed – particularly in pre-menopausal women and in those with dense breasts.

<!=> ATTENTION

Breasts symptoms should be given appropriate consideration despite a recent negative screening mammogram.

/ Breast Imaging

CHAPTER OUTLINE:

- Breast Anatomy
- Anatomical Variants
- Pregnancy and Lactation
- Diagnostic Imaging Techniques
- Disease of the Breast: Benign
- Disease of the Breast: Malignant
- Axilla
- Interventional Procedures
- Screening
- High Risk Women
- Communication**
 - / Mammography – Indications and Recommendations
- Multidisciplinary Team Meeting
- Take-Home Messages
- References
- Test Your Knowledge

/ When is Breast Ultrasound Recommended? <!=> ATTENTION

Ultrasound is an established tool for the work-up of suspected cancers.

It is the breast imaging method of choice in women under 40 years of age.

The European Society of Breast Imaging (EUSOBI) outlines the following definite indications for Breast Ultrasound:

- / Palpable lump
- / Axillary adenopathy
- / First approach for clinical breast abnormalities under age 40Y
- / First approach for clinical breast abnormalities in pregnant or lactating women
- / Suspicious abnormalities at mammography or MRI
- / Suspicious nipple discharge
- / Recent nipple inversion
- / Skin retraction
- / Breast inflammation
- / Abnormalities at the surgical scar after breast conserving surgery or mastectomy
- / Abnormalities in the presence of Breast Implants
- / Screening high-risk women, especially when MRI is not performed
- / Guidance for percutaneous breast interventions (needle biopsy, pre-surgical localisation, fluid collection drainage)
- / Monitoring patients with breast cancer receiving neo-adjuvant therapy, when MRI is not performed

/ Breast Imaging

CHAPTER OUTLINE:

- Breast Anatomy
- Anatomical Variants
- Pregnancy and Lactation
- Diagnostic Imaging Techniques
- Disease of the Breast: Benign
- Disease of the Breast: Malignant
- Axilla
- Interventional Procedures
- Screening
- High Risk Women
- Communication**
 - / Ultrasound – Indications
- Multidisciplinary Team Meeting
- Take-Home Messages
- References
- Test Your Knowledge

/ Can breast US be performed instead of mammography for breast cancer screening?

<!=> ATTENTION

Ultrasound may seem as a safe alternative to mammography – as it does not involve exposure to ionising radiation.

However, US has not been shown to reduce mortality from breast cancer in the general female population.

If US is used as a stand-alone screening tool instead of mammography, cancers could be missed, particularly in fatty breasts.

/ Breast Imaging

CHAPTER OUTLINE:

Breast Anatomy

Anatomical Variants

Pregnancy and Lactation

Diagnostic Imaging Techniques

Disease of the Breast: Benign

Disease of the Breast: Malignant

Axilla

Interventional Procedures

Screening

High Risk Women

Communication

/ Ultrasound – Indications

Multidisciplinary Team Meeting

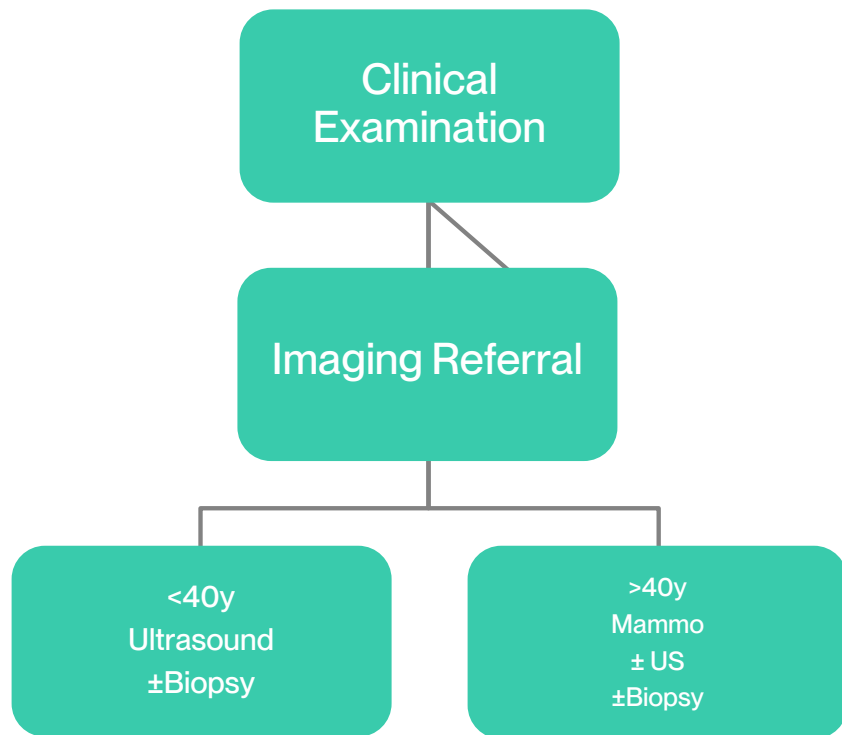
Take-Home Messages

References

Test Your Knowledge

/ Triple Assessment

Triple Assessment Schematic
of the Symptomatic Breast
Patient – may be performed
as part of a One Stop Clinic



/ Breast Imaging

CHAPTER OUTLINE:

Breast Anatomy
Anatomical Variants
Pregnancy and Lactation
Diagnostic Imaging Techniques
Disease of the Breast: Benign
Disease of the Breast: Malignant
Axilla
Interventional Procedures
Screening
High Risk Women
Communication
/ Triple Assessment
Multidisciplinary Team Meeting
Take-Home Messages
References
Test Your Knowledge

/ Breast Imaging Scenarios: Screening & Diagnostic

Imaging of the breast may be:

Screening of an asymptomatic cohort of clients assessed to pick up early disease changes

Breast screening is discussed in a dedicated chapter of this eBook.

Diagnostic:

Work-up of

- / A clinical finding eg lump, nipple changes or discharge, skin dimpling, breast inflammation
- / An incidental finding (breast finding on CT/MRI/PET Scan performed for a non-breast related indication)

/ Breast Imaging

CHAPTER OUTLINE:

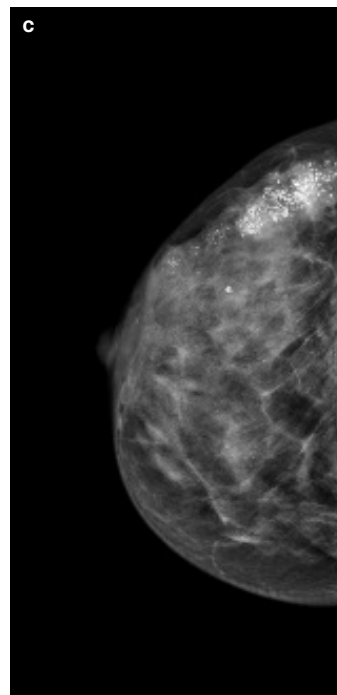
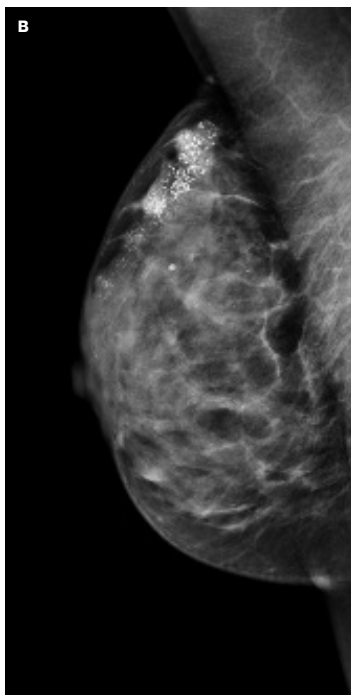
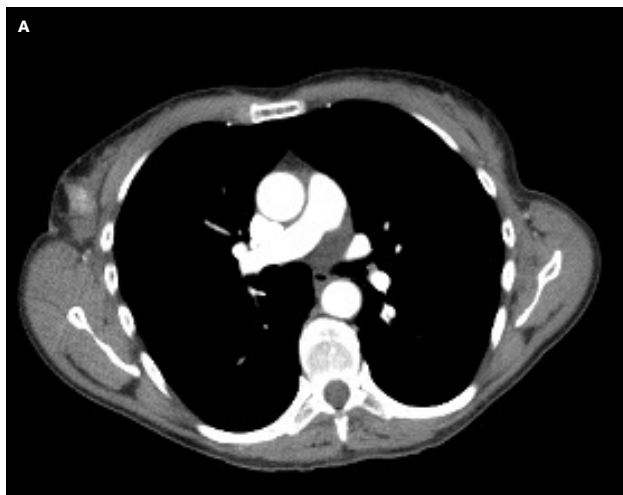
- Breast Anatomy
- Anatomical Variants
- Pregnancy and Lactation
- Diagnostic Imaging Techniques
- Disease of the Breast: Benign
- Disease of the Breast: Malignant
- Axilla
- Interventional Procedures
- Screening
- High Risk Women
- Communication**
 - / Breast Imaging Scenarios
- Multidisciplinary Team Meeting
- Take-Home Messages
- References
- Test Your Knowledge

/ Breast Imaging may be required as part of work-up for Incidental Breast findings on other imaging

/ Breast Imaging

CHAPTER OUTLINE:

- Breast Anatomy
- Anatomical Variants
- Pregnancy and Lactation
- Diagnostic Imaging Techniques
- Disease of the Breast: Benign
- Disease of the Breast: Malignant
- Axilla
- Interventional Procedures
- Screening
- High Risk Women
- Communication**
 - / Breast Imaging Scenarios
- Multidisciplinary Team Meeting
- Take-Home Messages
- References
- Test Your Knowledge



Indeterminate hyperdense lesion in the upper outer right breast on CT for investigation of weight loss in a 59 y old (A). Mammographic assessment demonstrates corresponding segmental heterogeneous microcalcifications (B,C).

/ Basic Considerations in Communicating with Patients

<!"> ATTENTION

- / Diagnostic breast imaging studies frequently reveal the need to obtain a definitive histological diagnosis.
- / The radiologist interprets the images, determines the need and performs the biopsy.
- / The radiologist receives the pathological results, determines concordance of the tissue diagnosis with the imaging concern and guides the patient toward the most appropriate treatment.
- / The radiologist is also uniquely positioned to enhance the patient's understanding and acceptance of the pathological findings with gentle and artful optimism.
- / To communicate with patients in order explain the benefits, risk and basic technical aspects of diagnostic imaging of the breast.
- / To communicate the benefits and risks of mammography screening.
- / To be able to communicate the results of a breast imaging examination, whenever necessary under supervision, to patients and their families based on the radiologic report by the end of the medical studies.
- / To be able to correctly suggest the most appropriate imaging examination depending on the clinical situation.

/ Breast Imaging

CHAPTER OUTLINE:

Breast Anatomy

Anatomical Variants

Pregnancy and Lactation

Diagnostic Imaging
TechniquesDisease of the Breast:
BenignDisease of the Breast:
Malignant

Axilla

Interventional Procedures

Screening

High Risk Women

Communication

- / Basic Considerations
in Communicating with
Patients

Multidisciplinary Team
Meeting

Take-Home Messages

References

Test Your Knowledge

CHAPTER OUTLINE:

Breast Anatomy

Anatomical Variants

Pregnancy and Lactation

Diagnostic Imaging
Techniques

Disease of the Breast:
Benign

Disease of the Breast:
Malignant

Axilla

Interventional Procedures

Screening

High Risk Women

Communication

**Multidisciplinary Team
Meeting**

Take-Home Messages

References

Test Your Knowledge

/ Multidisciplinary Team Meeting

/ Considerations in Communicating with Health Professionals

Standardisation of breast imaging report classification facilitates clear communication between referrer and the radiologist regarding the likelihood of malignant findings and the need for further investigation.

>=< FURTHER KNOWLEDGE

Comparison of Imaging Classification Systems

CATEGORY	BI-RADS	EUROPEAN/ROYAL COLLEGE OF RADIOLOGISTS BREAST GROUP
0	Incomplete assessment <i>Need to review priors and/or complete additional imaging</i>	
1	Negative	Normal/no significant abnormality
2	Benign finding	Benign finding
3	Probably benign findings (< 2% risk of malignancy). <i>Short-term follow-up review at 6 months, then every 6-12 months for 1-2 years)</i>	Indeterminate/probably benign findings. <i>There is a small risk of malignancy. Further investigation is indicated.</i>
4	Suspicious abnormality – biopsy recommended	Findings suspicious of malignancy There is a moderate risk of malignancy
5	Malignant findings	Findings highly suspicious of malignancy
6	Known biopsy-proven malignancy, treatment pending.	

/ Breast Imaging

CHAPTER OUTLINE:

Breast Anatomy
Anatomical Variants
Pregnancy and Lactation
Diagnostic Imaging Techniques
Disease of the Breast: Benign
Disease of the Breast: Malignant
Axilla
Interventional Procedures
Screening
High Risk Women
Communication
Multidisciplinary Team Meeting
Take-Home Messages
References
Test Your Knowledge



NCI Dictionary of Cancer Terms: “Treatment planning approach in which a number of doctors who are experts in different specialties (disciplines) review and discuss the medical condition and treatment options of a patient”.

Values that underlie an effective multidisciplinary team include:

- / effective communication and coordination
- / respect and trust
- / solid implementation strategies
- / transparency



/ Breast Imaging

CHAPTER OUTLINE:

- Breast Anatomy
- Anatomical Variants
- Pregnancy and Lactation
- Diagnostic Imaging Techniques
- Disease of the Breast: Benign
- Disease of the Breast: Malignant
- Axilla
- Interventional Procedures
- Screening
- High Risk Women
- Communication
- Multidisciplinary Team Meeting**
- Take-Home Messages
- References
- Test Your Knowledge

/ Multidisciplinary Team Meeting

<=> ATTENTION

All breast cancer specialists will attend the Multidisciplinary Team Meeting (MTM) on a regular basis in order to provide excellent breast cancer care: (oncoplastic) surgeon, medical oncologist, radiation oncologist, pathologist, radiologist and nuclear medicine physician.

The role for the radiologist at MTM is to demonstrate and explain imaging findings per patient, in order to facilitate a proper treatment plan in consensus with the other specialists.

If the management is agreed at MTM, treatment plan can be discussed with the patient.

In the case of discordant findings, repeat imaging with or without biopsy can be considered.



/ Breast Imaging

CHAPTER OUTLINE:

- Breast Anatomy
- Anatomical Variants
- Pregnancy and Lactation
- Diagnostic Imaging Techniques
- Disease of the Breast: Benign
- Disease of the Breast: Malignant
- Axilla
- Interventional Procedures
- Screening
- High Risk Women
- Communication
- Multidisciplinary Team Meeting**
- Take-Home Messages
- References
- Test Your Knowledge

/ Take-Home Messages

<=> ATTENTION

- / Imaging is used as part of **triple assessment** to diagnose and exclude disease.
- / **Mammography** is the cornerstone of breast imaging, playing a crucial role as the screening imaging technique in women with average-risk of developing breast cancer.
- / **DBT** is a mammography-based imaging technique that produces quasi-3D images of the breast, reducing the limitations of 2D imaging (overlapping tissues) and improving the detection and the delineation of findings, increasing the sensitivity and the specificity.
- / **CEM** is a relatively new mammography-based imaging technique that relies on the intravenous administration of an iodinated contrast agent to highlight areas of increased contrast agent uptake; currently it can be considered as an alternative for women with contraindications to breast MRI.
- / **Breast US** is a dynamic non-ionising, accessible and cheap imaging technique that plays a very important role in the everyday practice by providing additional screening in women with dense breasts, by allowing direct real-time correlation of imaging and clinical findings and by guiding biopsies and other interventional procedure.
- / **Breast MRI** is a multiparametric imaging technique that has changed Breast Imaging, playing a very important role in different scenarios, such as in breast cancer staging, in the evaluation of response to neoadjuvant therapy and in the screening of women with high-risk of developing breast cancer and in women with extremely dense breasts.
- / **Image guided biopsy** for diagnosis are used extensively; minimally invasive treatment becoming more popular in good prognosis disease such as DCIS and **low grade cancer**.

/ Breast Imaging

CHAPTER OUTLINE:

Breast Anatomy
Anatomical Variants
Pregnancy and Lactation
Diagnostic Imaging Techniques
Disease of the Breast: Benign
Disease of the Breast: Malignant
Axilla
Interventional Procedures
Screening
High Risk Women
Communication
Multidisciplinary Team Meeting
Take-Home Messages
References
Test Your Knowledge

<=> ATTENTION

- / Knowledge of the anatomy, anatomical variants and changes during pregnancy and lactation is important to recognise disease.
- / Imaging findings should be evaluated together with signs and symptoms. They should be compared with previous examinations.
- / **Mammography** is the first-line imaging tool for patients over 40 years of age. Targeted ultrasound can be done in the presence of suspicious findings or if the patient has an extremely dense breast.
- / **Ultrasound** is the first-line imaging tool for patients under 40 years of age.
- / **Benign diseases** of the breast, especially cysts and fibroadenomas are the most common and symptomatic masses in women.
- / **Contrast-enhanced MRI** is a problem-solving tool with the highest sensitivity and negative predictive value for breast cancer detection.
- / Some high-grade aggressive tumours (medullary type, grade 3 or triple-negative type etc.) can mimic benign masses on mammography/ultrasound. In patients with a family history, attention should be paid to newly developing lesions or masses showing increased size during follow-up. These masses should be confirmed by biopsy.
- / Imaging the axilla to determine if there any abnormal lymph nodes is part of preoperative staging
- / Clear communication of results with a management plan is part of the role of the radiologist.

Breast Imaging

CHAPTER OUTLINE:

Breast Anatomy
Anatomical Variants
Pregnancy and Lactation
Diagnostic Imaging Techniques
Disease of the Breast: Benign
Disease of the Breast: Malignant
Axilla
Interventional Procedures
Screening
High Risk Women
Communication
Multidisciplinary Team Meeting
Take-Home Messages
References
Test Your Knowledge

/ References

Breast Anatomy

- / <https://www.acr.org/Clinical-Resources/Reporting-and-Da-ta-Systems/Bi-Rads>

Anatomical Variants

- / Wendie A. Berg & Jessica: Leung Diagnostic Imaging: Breast, 3rd Edition Authors Date of Publication: 09/2019
- / García CJ, Espinoza A, Dinamarca V, Navarro O, Daneman A, García H, Cattani A. Breast US in children and adolescents. Radiographics. 2000 Nov-Dec;20(6):1605-12. doi: 10.1148/radiographics.20.6.g00nv171605. PMID: 11112814.
- / Chung EM, Cube R, Hall GJ, González C, Stocker JT, Glassman LM. From the archives of the AFIP: breast masses in children and adolescents: radiologic-pathologic correlation. Radiographics. 2009 May-Jun;29(3):907-31. doi: 10.1148/rg.293095010. PMID: 19448124.

Pregnancy and Lactation

- / Kaneda HJ, Mack J, Kasales CJ, Schetter S. Pediatric and adolescent breast masses: a review of pathophysiology, imaging, diagnosis, and treatment. AJR Am J Roentgenol. 2013 Feb;200(2):W204-12. doi: 10.2214/AJR.12.9560. PMID: 23345385.
- / de Holanda AA, Gonçalves AK, de Medeiros RD, de Oliveira AM, Maranhão TM. Ultrasound findings of the physiological changes and most common breast diseases during pregnancy and lactation. Radiol Bras. 2016 Nov-Dec;49(6):389-396. doi: 10.1590/0100-3984.2015.0076. PMID: 28057965; PMCID: PMC5210035.
- / Nissan N, Bauer E, Moss Massasa EE, Sklair-Levy M. Breast MRI during pregnancy and lactation: clinical challenges and technical advances. Insights Imaging. 2022 Apr 9;13(1):71. doi: 10.1186/s13244-022-01214-7. PMID: 35397082; PMCID: PMC8994812.

/ Breast Imaging

CHAPTER OUTLINE:

Breast Anatomy

Anatomical Variants

Pregnancy and Lactation

Diagnostic Imaging
TechniquesDisease of the Breast:
BenignDisease of the Breast:
Malignant

Axilla

Interventional Procedures

Screening

High Risk Women

Communication

Multidisciplinary Team
Meeting

Take-Home Messages

References

Test Your Knowledge

Diagnostic Imaging Techniques

- / Joe, B.N. and Lee, A.Y. (2022) Breast Imaging: The Core Requisites. 4th edn. Philadelphia, PA: Elsevier (The Core Requisites).
- / Berg, W.A. and Leung, J.W.T. (2019) Diagnostic Imaging: Breast. 3rd edn. Philadelphia, PA: Elsevier.
- / Fuchsjäger M., Morris E., Helbich T.H., Breast Imaging: Diagnosis and Intervention. 1st edn. Springer.
- / European Commission. European Guidelines for Quality Assurance in Breast Cancer Screening and Diagnosis. 4th edition. In Perry N, Broeders M, de Wolf C et al. (eds): Office for Official Publications of the European Communities, Luxembourg: 2006.
- / Kopans D. B. (2014). Digital breast tomosynthesis from concept to clinical care. AJR. American journal of roentgenology, 202(2), 299–308. <https://doi.org/10.2214/AJR.13.11520>.
- / Sensakovic WF, Carnahan MB, Czaplicki CD, Fahrenholtz S, Panda A, Zhou Y, Pavlicek W, Patel B. Contrast-enhanced Mammography: How Does It Work? Radiographics. 2021 May-Jun;41(3):829-839. doi: 10.1148/rg.2021200167. Epub 2021 Apr 9. PMID: 33835871.
- / Galati F, Moffa G, Pediconi F. Breast imaging: Beyond the detection. Eur J Radiol. 2022 Jan;146:110051. doi: 10.1016/j.ejrad.2021.110051. Epub 2021 Nov 19. PMID: 34864426.

Disease of the Breast: Benign

- / Berg WA et al. Cystic lesions of the breast: sonographic-pathologic correlation. Radiology. 2003;227(1):183-91
- / Wendie A. Berg, Jessica Leung. Diagnostic Imaging Breast (2019, Elsevier).
- / Oligane HC et al. Grouped amorphous calcifications at mammography: frequently atypical but rarely associated with aggressive malignancy. Radiology. 2018; 288(3):671-679
- / Chao TC, Chao HH, Chen MF. Sonographic features of breast hamartomas. J Ultrasound Med. 2007;26 (4): 447-52.
- / Malherbe K, Khan M, Fatima S. Fibrocystic Breast Disease. [Updated 2022 Aug 8]. In: StatPearls [Internet].
- / Bonnie N.Joe, Amie Y. Lee. The core requisites (4th edition, Elsevier)
- / Cheng L et al. Mastitis, a radiographic, clinical, and histopathologic review. Breast J. 2015; 21(4):403-9
- / Trop I et al. Breast abscesses: evidence-based algorithms for diagnosis, management, and follow-up. Radiographics. 2011; 31(6):1683-99
- / Mahoney MC et al. Breast emergencies: types, imaging features, and management. AJR Am J Roentgenol. 2014; 202(4):W390-9.
- / Hassan HHM et al. Fat necrosis of the breast: magnetic resonance imaging characteristics and pathologic correlation. Acad Radiol. 2018; 25(8):985-92
- / Taboada J, Stephens T, Krishnamurthy S, Brandt K, Whitman G. The Many Faces of Fat Necrosis in the Breast. AJR Am J Roentgenol. 2009;192(3):815-25
- / Ritse M. Mann, Nariya Cho, and Linda Moy. Breast MRI: State of the Art. Radiology. 2019; 292:3, 520-536

/ Breast Imaging

CHAPTER OUTLINE:

Breast Anatomy

Anatomical Variants

Pregnancy and Lactation

Diagnostic Imaging Techniques

Disease of the Breast: Benign

Disease of the Breast: Malignant

Axilla

Interventional Procedures

Screening

High Risk Women

Communication

Multidisciplinary Team Meeting

Take-Home Messages

References

Test Your Knowledge

Interventional Procedures

- / Bick U, Trimboli RM, Athanasiou A et al. Image-guided breast biopsy and localisation: recommendations for information to women and referring physicians by the European Society of Breast Imaging. *Insights Imaging*. 2020 Feb 5;11(1):12. doi: 10.1186/s13244-019-0803-x.
- / O'Flynn EA, Wilson AR, Michell MJ. Image-guided breast biopsy: state-of-the-art. *Clin Radiol*. 2010 Apr;65(4):259-70. doi: 10.1016/j.crad.2010.01.008.
- / Giannotti E, James JJ, Chen Y, Sun R, Karuppiyah A, Yemm J, Lee AHS. Effectiveness of percutaneous vacuum-assisted excision (VAE) of breast lesions of uncertain malignant potential (B3 lesions) as an alternative to open surgical biopsy. *Eur Radiol*. 2021 Dec;31(12):9540-9547. doi: 10.1007/s00330-021-08060-z. Epub 2021 Jun 8. Erratum in: *Eur Radiol*. 2021 Jul 5; PMID: 34100998
- / Mauri G, Sconfienza LM, Pescatori LC, Fedeli MP, Ali M, Di Leo G, Sardanelli F. Technical success, technique efficacy and complications of minimally-invasive imaging-guided percutaneous ablation procedures of breast cancer: A systematic review and meta-analysis. *Eur Radiol*. 2017 Aug;27(8):3199-3210. doi: 10.1007/s00330-016-4668-9.
- / Sharma N, Cornford E, Cheung S, Price H, Kearins O. The impact of vacuum-assisted excision in the management of indeterminate B3 lesions in the NHS Breast Screening Programme in England. *Clin Radiol*. 2021 Jun;76(6):470.e23-470.e29. doi: 10.1016/j.crad.2021.01.021.

Screening

- / IDoR Publication 2016 SCREENING & BEYOND Medical imaging in the Detection, Diagnosis and Management of Breast Diseases https://www.internationaldayofradiology.com/app/uploads/2017/09/IDoR-2016_Book-on-Breast-Imaging_Web_low.pdf
- / Sardanelli F, Fallenberg EM, Clauser P, Trimboli R, Camps-Herrero J, Helbich TH, Forrai G. Mammography: an update of the EUSOBI recommendations on information for women. <https://www.eusobi.org/breast-imaging-publications-and-guidelines/>
- / Yaffe MJ, Jong RA, Pritchard, KI. Breast Cancer Screening: Beyond Mortality. *Journal of Breast Imaging*, Volume 1, Issue 3 September 2019, Pages 161-165
- / <https://healthcare-quality.jrc.ec.europa.eu/ecibc/europe-an-breast-cancer-guidelines/screening-ages-and-frequencies>

/ Breast Imaging

CHAPTER OUTLINE:

Breast Anatomy

Anatomical Variants

Pregnancy and Lactation

Diagnostic Imaging Techniques

Disease of the Breast: Benign

Disease of the Breast: Malignant

Axilla

Interventional Procedures

Screening

High Risk Women

Communication

Multidisciplinary Team Meeting

Take-Home Messages

References

Test Your Knowledge

High Risk Women

- / Monticciolo DL, Newell MS, Moy L, Niell B, Monsees B, Sickles EA. Breast Cancer Screening in Women at Higher-Than-Average Risk: Recommendations From the ACR. *J Am Coll Radiol*. 2018 Mar;15(3 Pt A):408-414. doi: 10.1016/j.jacr.2017.11.034.
- / Sardanelli F et al. Position paper on screening for breast cancer by the European Society of Breast Imaging (EUSOBI) and 30 national breast radiology bodies from Austria, Belgium, Bosnia and Herzegovina, Bulgaria, Croatia, Czech Republic, Denmark, Estonia, Finland, France, Germany, Greece, Hungary, Iceland, Ireland, Italy, Israel, Lithuania, Moldova, The Netherlands, Norway, Poland, Portugal, Romania, Serbia, Slovakia, Spain, Sweden, Switzerland and Turkey. *Eur Radiol*. 2017 Jul;27(7):2737-2743. doi: 10.1007/s00330-016-4612-z.
- / Thomas PS. Diagnosis and Management of High-Risk Breast Lesions. *J Natl Compr Canc Netw*. 2018 Nov;16(11):1391-1396. doi: 10.6004/jnccn.2018.7099.
- / Mann RM et al. European Society of Breast Imaging (EUSOBI). Breast cancer screening in women with extremely dense breasts recommendations of the European Society of Breast Imaging (EUSOBI). *Eur Radiol*. 2022 Jun;32(6):4036-4045. doi: 10.1007/s00330-022-08617-6.

Communication

- / IDoR Publication 2016 SCREENING & BEYOND Medical imaging in the Detection, Diagnosis and Management of Breast Diseases https://www.internationaldayofradiology.com/app/uploads/2017/09/IDoR-2016_Book-on-Breast-Imaging_Web_low.pdf
- / Sardanelli F, Fallenberg EM, Clauser P, Trimboli R, Camps-Herrero J, Helbich TH, Forrai G. Mammography: an update of the EUSOBI recommendations on information for women. <https://www.eusobi.org/breast-imaging-publications-and-guidelines/>
- / Evans A, Trimboli RM, Athanasiou A, Balleyguier C, Baltzer P et al Breast ultrasound: recommendations for information to women and referring physicians by the European Society of Breast Imaging. <https://www.eusobi.org/breast-imaging-publications-and-guidelines/>
- / Maxwell AJ, Ridley NT, Rubin G, Wallis MG, Gilbert FJ and Michell M The Royal College of Radiologists Breast Group breast imaging classification. *Clinical Radiology*, 64, 2009, Pages 624-627

Breast Imaging

CHAPTER OUTLINE:

- Breast Anatomy
- Anatomical Variants
- Pregnancy and Lactation
- Diagnostic Imaging Techniques
- Disease of the Breast: Benign
- Disease of the Breast: Malignant
- Axilla
- Interventional Procedures
- Screening
- High Risk Women
- Communication
- Multidisciplinary Team Meeting
- Take-Home Messages
- References
- Test Your Knowledge

CHAPTER OUTLINE:

Breast Anatomy

Anatomical Variants

Pregnancy and Lactation

Diagnostic Imaging
Techniques

Disease of the Breast:
Benign

Disease of the Breast:
Malignant

Axilla

Interventional Procedures

Screening

High Risk Women

Communication

Multidisciplinary Team
Meeting

Take-Home Messages

References

Test Your Knowledge

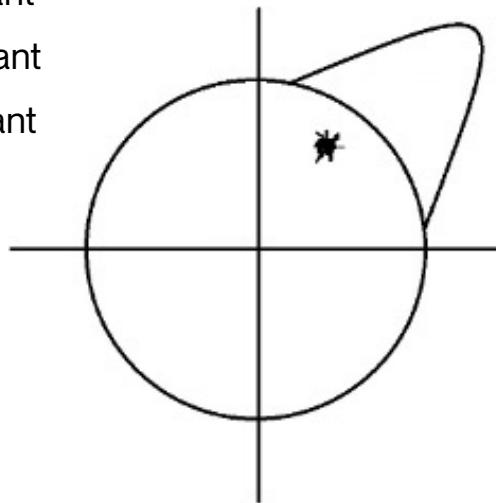
/ Test Your Knowledge

/ Test Your Knowledge

<?> QUESTION

1 How would you describe the location of the lesion?

- ☐ Upper outer quadrant
- ☐ Upper inner quadrant
- ☐ Lower outer quadrant
- ☐ Lower inner quadrant



/ Breast Imaging

CHAPTER OUTLINE:

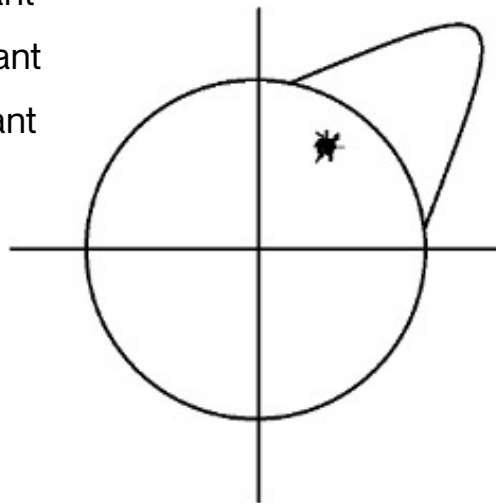
Breast Anatomy
Anatomical Variants
Pregnancy and Lactation
Diagnostic Imaging Techniques
Disease of the Breast: Benign
Disease of the Breast: Malignant
Axilla
Interventional Procedures
Screening
High Risk Women
Communication
Multidisciplinary Team Meeting
Take-Home Messages
References
Test Your Knowledge

/ Test Your Knowledge

<?> ANSWER

1 How would you describe the location of the lesion?

- ☒ Upper outer quadrant
- ☐ Upper inner quadrant
- ☐ Lower outer quadrant
- ☐ Lower inner quadrant



/ Breast Imaging

CHAPTER OUTLINE:

Breast Anatomy
Anatomical Variants
Pregnancy and Lactation
Diagnostic Imaging Techniques
Disease of the Breast: Benign
Disease of the Breast: Malignant
Axilla
Interventional Procedures
Screening
High Risk Women
Communication
Multidisciplinary Team Meeting
Take-Home Messages
References
Test Your Knowledge

/ Test Your Knowledge

<?> QUESTION

2 What is the name of the syndrome consisting of unilateral partial or complete absence of the m. pectoralis, with associated breast hypo/aplasia and possible rib/chest wall deformities?

- ☐ Holland syndrome
- ☐ Poland syndrome
- ☐ Germany syndrome
- ☐ Switzerland syndrome

/ Breast Imaging

CHAPTER OUTLINE:

Breast Anatomy
Anatomical Variants
Pregnancy and Lactation
Diagnostic Imaging Techniques
Disease of the Breast: Benign
Disease of the Breast: Malignant
Axilla
Interventional Procedures
Screening
High Risk Women
Communication
Multidisciplinary Team Meeting
Take-Home Messages
References
Test Your Knowledge

/ Test Your Knowledge

<?> ANSWER

2 What is the name of the syndrome consisting of unilateral partial or complete absence of the m. pectoralis, with associated breast hypo/aplasia and possible rib/chest wall deformities?

- ☐ Holland syndrome
- ☒ Poland syndrome
- ☐ Germany syndrome
- ☐ Switzerland syndrome

/ Breast Imaging

CHAPTER OUTLINE:

Breast Anatomy
Anatomical Variants
Pregnancy and Lactation
Diagnostic Imaging Techniques
Disease of the Breast: Benign
Disease of the Breast: Malignant
Axilla
Interventional Procedures
Screening
High Risk Women
Communication
Multidisciplinary Team Meeting
Take-Home Messages
References
Test Your Knowledge

/ Test Your Knowledge

<?> QUESTION

3 Pregnancy and Lactation: What are the most seen ultrasound findings in a lactating breast?

- ☐ Decreased parenchymal echogeniety and cysts
- ☐ Decreased parenchymal echogeniety and dilated ducts
- ☐ Increased parenchymal echogeniety and cysts
- ☐ Increased parenchymal echogeniety and dilated ducts

/ Breast Imaging

CHAPTER OUTLINE:

Breast Anatomy
Anatomical Variants
Pregnancy and Lactation
Diagnostic Imaging Techniques
Disease of the Breast: Benign
Disease of the Breast: Malignant
Axilla
Interventional Procedures
Screening
High Risk Women
Communication
Multidisciplinary Team Meeting
Take-Home Messages
References
Test Your Knowledge

/ Test Your Knowledge

<?> ANSWER

3 Pregnancy and Lactation: What are the most seen ultrasound findings in a lactating breast?

- ☐ Decreased parenchymal echogeniety and cysts
- ☐ Decreased parenchymal echogeniety and dilated ducts
- ☐ Increased parenchymal echogeniety and cysts
- ☒ Increased parenchymal echogeniety and dilated ducts

/ Breast Imaging

CHAPTER OUTLINE:

Breast Anatomy
Anatomical Variants
Pregnancy and Lactation
Diagnostic Imaging Techniques
Disease of the Breast: Benign
Disease of the Breast: Malignant
Axilla
Interventional Procedures
Screening
High Risk Women
Communication
Multidisciplinary Team Meeting
Take-Home Messages
References
Test Your Knowledge

/ Test Your Knowledge

<?> QUESTION

4

Regarding Breast Ultrasound (US), select the TRUE statement:

- ☐ Breast US is an imaging technique that exploits the magnetism of the protons that constitute the breast (and surrounding) tissues to create diagnostic images.
- ☐ The American College of Radiology (ACR) recommends performing Breast US using low-frequency transducers, with a broad bandwidth operating at a centre frequency of no more than 5 MHz.
- ☐ Elastography is a modality of Breast US that allows the evaluation of stiffness.
- ☐ One of the main advantages of Breast US is that it is an “operator-independent” imaging technique.
- ☐ Breast US is contraindicated in the evaluation of symptomatic young or lactating patients.

/ Breast Imaging

CHAPTER OUTLINE:

Breast Anatomy
Anatomical Variants
Pregnancy and Lactation
Diagnostic Imaging Techniques
Disease of the Breast: Benign
Disease of the Breast: Malignant
Axilla
Interventional Procedures
Screening
High Risk Women
Communication
Multidisciplinary Team Meeting
Take-Home Messages
References
Test Your Knowledge

/ Test Your Knowledge

<?> ANSWER

4

Regarding Breast Ultrasound (US), select the TRUE statement:

- ☐ Breast US is an imaging technique that exploits the magnetism of the protons that constitute the breast (and surrounding) tissues to create diagnostic images.
- ☐ The American College of Radiology (ACR) recommends performing Breast US using low-frequency transducers, with a broad bandwidth operating at a centre frequency of no more than 5 MHz.
- ☒ Elastography is a modality of Breast US that allows the evaluation of stiffness.
- ☐ One of the main advantages of Breast US is that it is an “operator-independent” imaging technique.
- ☐ Breast US is contraindicated in the evaluation of symptomatic young or lactating patients.

/ Breast Imaging

CHAPTER OUTLINE:

Breast Anatomy
Anatomical Variants
Pregnancy and Lactation
Diagnostic Imaging Techniques
Disease of the Breast: Benign
Disease of the Breast: Malignant
Axilla
Interventional Procedures
Screening
High Risk Women
Communication
Multidisciplinary Team Meeting
Take-Home Messages
References
Test Your Knowledge

/ Test Your Knowledge

<?> QUESTION

5

Which of the following characteristic does NOT indicate a malignancy on ultrasound?

- ☐ Irregular shape
- ☐ Shadowing
- ☐ Parallel orientation
- ☐ Not-circumscribed margins

/ Breast Imaging

CHAPTER OUTLINE:

Breast Anatomy
Anatomical Variants
Pregnancy and Lactation
Diagnostic Imaging Techniques
Disease of the Breast: Benign
Disease of the Breast: Malignant
Axilla
Interventional Procedures
Screening
High Risk Women
Communication
Multidisciplinary Team Meeting
Take-Home Messages
References
Test Your Knowledge

/ Test Your Knowledge

<?> ANSWER

5 Which of the following characteristic does NOT indicate a malignancy on ultrasound?

- ☐ Irregular shape
- ☐ Shadowing
- ☒ Parallel orientation
- ☐ Not-circumscribed margins

/ Breast Imaging

CHAPTER OUTLINE:

Breast Anatomy
Anatomical Variants
Pregnancy and Lactation
Diagnostic Imaging Techniques
Disease of the Breast: Benign
Disease of the Breast: Malignant
Axilla
Interventional Procedures
Screening
High Risk Women
Communication
Multidisciplinary Team Meeting
Take-Home Messages
References
Test Your Knowledge

/ Test Your Knowledge

<?> QUESTION

6 Which of these is a main advantage of breast Magnetic Resonance?

- ☐ High soft-tissue contrast
- ☐ Costs
- ☐ Scanning times
- ☐ Use in claustrophobic patients

/ Breast Imaging

CHAPTER OUTLINE:

Breast Anatomy
Anatomical Variants
Pregnancy and Lactation
Diagnostic Imaging Techniques
Disease of the Breast: Benign
Disease of the Breast: Malignant
Axilla
Interventional Procedures
Screening
High Risk Women
Communication
Multidisciplinary Team Meeting
Take-Home Messages
References
Test Your Knowledge

/ Test Your Knowledge

<?> ANSWER

6 Which of these is a main advantage of breast Magnetic Resonance?

- ☒ High soft-tissue contrast
- ☐ Costs
- ☐ Scanning times
- ☐ Use in claustrophobic patients

/ Breast Imaging

CHAPTER OUTLINE:

Breast Anatomy
Anatomical Variants
Pregnancy and Lactation
Diagnostic Imaging Techniques
Disease of the Breast: Benign
Disease of the Breast: Malignant
Axilla
Interventional Procedures
Screening
High Risk Women
Communication
Multidisciplinary Team Meeting
Take-Home Messages
References
Test Your Knowledge

/ Test Your Knowledge

<?> QUESTION

7 Regarding Breast Magnetic Resonance Imaging (MRI) and Contrast-enhanced Mammography (CEM), select the FALSE statement:

- ☐ Breast MRI is an imaging technique that uses sound waves to visualise breast tissue.
- ☐ Comparing to other imaging techniques, Breast MRI produces images with superior soft-tissue contrast.
- ☐ Breast MRI is useful in the evaluation of breast implants.
- ☐ CEM is an imaging technique based on dual-energy mammographic acquisition after intravenous administration of an iodinated contrast agent.
- ☐ The Field of View (FoV) of CEM is limited comparing to that of Breast MRI.

/ **Breast Imaging**

CHAPTER OUTLINE:

Breast Anatomy
Anatomical Variants
Pregnancy and Lactation
Diagnostic Imaging Techniques
Disease of the Breast: Benign
Disease of the Breast: Malignant
Axilla
Interventional Procedures
Screening
High Risk Women
Communication
Multidisciplinary Team Meeting
Take-Home Messages
References
Test Your Knowledge

/ Test Your Knowledge

<?> ANSWER

7 Regarding Breast Magnetic Resonance Imaging (MRI) and Contrast-enhanced Mammography (CEM), select the FALSE statement:

- ☒ Breast MRI is an imaging technique that uses sound waves to visualise breast tissue.
- ☐ Comparing to other imaging techniques, Breast MRI produces images with superior soft-tissue contrast.
- ☐ Breast MRI is useful in the evaluation of breast implants.
- ☐ CEM is an imaging technique based on dual-energy mammographic acquisition after intravenous administration of an iodinated contrast agent.
- ☐ The Field of View (FoV) of CEM is limited comparing to that of Breast MRI.

/ **Breast Imaging**

CHAPTER OUTLINE:

Breast Anatomy
Anatomical Variants
Pregnancy and Lactation
Diagnostic Imaging Techniques
Disease of the Breast: Benign
Disease of the Breast: Malignant
Axilla
Interventional Procedures
Screening
High Risk Women
Communication
Multidisciplinary Team Meeting
Take-Home Messages
References
Test Your Knowledge

/ Test Your Knowledge

<?> QUESTION

8

What should a breast imaging report contain?

- ☐ Clinical information and indication
- ☐ Breast density - Tissue composition-enhancement pattern
- ☐ Assessment category
- ☐ Recommendations
- ☐ All

/ Breast Imaging

CHAPTER OUTLINE:

Breast Anatomy
Anatomical Variants
Pregnancy and Lactation
Diagnostic Imaging Techniques
Disease of the Breast: Benign
Disease of the Breast: Malignant
Axilla
Interventional Procedures
Screening
High Risk Women
Communication
Multidisciplinary Team Meeting
Take-Home Messages
References
Test Your Knowledge

/ Test Your Knowledge

<?> ANSWER

8

What should a breast imaging report contain?

- ☐ Clinical information and indication
- ☐ Breast density - Tissue composition-enhancement pattern
- ☐ Assessment category
- ☐ Recommendations
- ☒ All

/ Breast Imaging

CHAPTER OUTLINE:

Breast Anatomy
Anatomical Variants
Pregnancy and Lactation
Diagnostic Imaging Techniques
Disease of the Breast: Benign
Disease of the Breast: Malignant
Axilla
Interventional Procedures
Screening
High Risk Women
Communication
Multidisciplinary Team Meeting
Take-Home Messages
References
Test Your Knowledge

/ Test Your Knowledge

<?> QUESTION

9 Which of the following is included in the Triple Assessment of a suspicious breast lesion?

- ☐ Surgery
- ☐ Radiotherapy
- ☐ Clinical examination
- ☐ Family history

/ Breast Imaging

CHAPTER OUTLINE:

Breast Anatomy
Anatomical Variants
Pregnancy and Lactation
Diagnostic Imaging Techniques
Disease of the Breast: Benign
Disease of the Breast: Malignant
Axilla
Interventional Procedures
Screening
High Risk Women
Communication
Multidisciplinary Team Meeting
Take-Home Messages
References
Test Your Knowledge

/ Test Your Knowledge

<?> ANSWER

9 Which of the following is included in the Triple Assessment of a suspicious breast lesion?

- ☐ Surgery
- ☐ Radiotherapy
- ☒ Clinical examination
- ☐ Family history

/ Breast Imaging

CHAPTER OUTLINE:

Breast Anatomy
Anatomical Variants
Pregnancy and Lactation
Diagnostic Imaging Techniques
Disease of the Breast: Benign
Disease of the Breast: Malignant
Axilla
Interventional Procedures
Screening
High Risk Women
Communication
Multidisciplinary Team Meeting
Take-Home Messages
References
Test Your Knowledge

/ Test Your Knowledge

<?> QUESTION

10 What is the best imaging modality to depict cysts?

- ☐ Mammography
- ☐ Ultrasound
- ☐ MR
- ☐ CT

/ Breast Imaging

CHAPTER OUTLINE:

Breast Anatomy
Anatomical Variants
Pregnancy and Lactation
Diagnostic Imaging Techniques
Disease of the Breast: Benign
Disease of the Breast: Malignant
Axilla
Interventional Procedures
Screening
High Risk Women
Communication
Multidisciplinary Team Meeting
Take-Home Messages
References
Test Your Knowledge

/ Test Your Knowledge

<?> ANSWER

10 What is the best imaging modality to depict cysts?

- ☐ Mammography
- ☒ Ultrasound
- ☐ MR
- ☐ CT

/ Breast Imaging

CHAPTER OUTLINE:

Breast Anatomy
Anatomical Variants
Pregnancy and Lactation
Diagnostic Imaging Techniques
Disease of the Breast: Benign
Disease of the Breast: Malignant
Axilla
Interventional Procedures
Screening
High Risk Women
Communication
Multidisciplinary Team Meeting
Take-Home Messages
References
Test Your Knowledge

/ Test Your Knowledge

<?> QUESTION

11

Fibroadenoma:

- ☐ is a malignant breast disease.
- ☐ is the most common solid mass in woman of all ages.
- ☐ necessitates biopsy if its diameter increases by more than 20 percent within 6 months.
- ☐ presents as a firm mass adherent to the surrounding tissue.

/ Breast Imaging

CHAPTER OUTLINE:

Breast Anatomy
Anatomical Variants
Pregnancy and Lactation
Diagnostic Imaging Techniques
Disease of the Breast: Benign
Disease of the Breast: Malignant
Axilla
Interventional Procedures
Screening
High Risk Women
Communication
Multidisciplinary Team Meeting
Take-Home Messages
References
Test Your Knowledge

/ Test Your Knowledge

<?> ANSWER

11

Fibroadenoma:

- ☐ is a malignant breast disease.
- ☒ is the most common solid mass in woman of all ages.
- ☒ necessitates biopsy if its diameter increases by more than 20 percent within 6 months.
- ☐ presents as a firm mass adherent to the surrounding tissue.

/ Breast Imaging

CHAPTER OUTLINE:

Breast Anatomy
Anatomical Variants
Pregnancy and Lactation
Diagnostic Imaging Techniques
Disease of the Breast: Benign
Disease of the Breast: Malignant
Axilla
Interventional Procedures
Screening
High Risk Women
Communication
Multidisciplinary Team Meeting
Take-Home Messages
References
Test Your Knowledge

/ Test Your Knowledge

<?> QUESTION

12 Regarding Hamartoma, select the FALSE statement:

- ☐ can present as vague breast mass.
- ☐ contains integral epithelial and stromal components.
- ☐ can enlarge.
- ☐ needs core biopsy.

/ Breast Imaging

CHAPTER OUTLINE:

Breast Anatomy
Anatomical Variants
Pregnancy and Lactation
Diagnostic Imaging Techniques
Disease of the Breast: Benign
Disease of the Breast: Malignant
Axilla
Interventional Procedures
Screening
High Risk Women
Communication
Multidisciplinary Team Meeting
Take-Home Messages
References
Test Your Knowledge

/ Test Your Knowledge

<?> ANSWER

12 Regarding Hamartoma, select the FALSE statement:

- ☐ can present as vague breast mass.
- ☐ contains integral epithelial and stromal components.
- ☐ can enlarge.
- ☒ needs core biopsy.

/ Breast Imaging

CHAPTER OUTLINE:

Breast Anatomy
Anatomical Variants
Pregnancy and Lactation
Diagnostic Imaging Techniques
Disease of the Breast: Benign
Disease of the Breast: Malignant
Axilla
Interventional Procedures
Screening
High Risk Women
Communication
Multidisciplinary Team Meeting
Take-Home Messages
References
Test Your Knowledge

/ Test Your Knowledge

<?> QUESTION

13 Select the predisposing conditions for fat necrosis.

- ☐ Blunt trauma
- ☐ Surgery
- ☐ Spontaneous in diabetic patients
- ☐ Lipoma

/ Breast Imaging

CHAPTER OUTLINE:

Breast Anatomy
Anatomical Variants
Pregnancy and Lactation
Diagnostic Imaging Techniques
Disease of the Breast: Benign
Disease of the Breast: Malignant
Axilla
Interventional Procedures
Screening
High Risk Women
Communication
Multidisciplinary Team Meeting
Take-Home Messages
References
Test Your Knowledge

/ Test Your Knowledge

<?> ANSWER

13 Select the predisposing conditions for fat necrosis.

- ☐ Blunt trauma
- ☒ Surgery
- ☐ Spontaneous in diabetic patients
- ☐ Lipoma

/ Breast Imaging

CHAPTER OUTLINE:

Breast Anatomy
Anatomical Variants
Pregnancy and Lactation
Diagnostic Imaging Techniques
Disease of the Breast: Benign
Disease of the Breast: Malignant
Axilla
Interventional Procedures
Screening
High Risk Women
Communication
Multidisciplinary Team Meeting
Take-Home Messages
References
Test Your Knowledge

/ Test Your Knowledge

<?> QUESTION

14 Which of the following minimal invasive treatments does NOT use electromagnetic waves to achieve local tumour ablation?

- ☐ Radiofrequency
- ☐ Microwaves
- ☐ Laser ablation
- ☐ Cryoablation

/ Breast Imaging

CHAPTER OUTLINE:

Breast Anatomy
Anatomical Variants
Pregnancy and Lactation
Diagnostic Imaging Techniques
Disease of the Breast: Benign
Disease of the Breast: Malignant
Axilla
Interventional Procedures
Screening
High Risk Women
Communication
Multidisciplinary Team Meeting
Take-Home Messages
References
Test Your Knowledge

/ Test Your Knowledge

<?> ANSWER

14 Which of the following minimal invasive treatments does NOT use electromagnetic waves to achieve local tumour ablation?

- ☐ Radiofrequency
- ☐ Microwaves
- ☐ Laser ablation
- ☒ Cryoablation

/ Breast Imaging

CHAPTER OUTLINE:

Breast Anatomy
Anatomical Variants
Pregnancy and Lactation
Diagnostic Imaging Techniques
Disease of the Breast: Benign
Disease of the Breast: Malignant
Axilla
Interventional Procedures
Screening
High Risk Women
Communication
Multidisciplinary Team Meeting
Take-Home Messages
References
Test Your Knowledge

/ Test Your Knowledge

<?> QUESTION

15 Which of these factors is associated with an increased risk of breast cancer?

- ☐ Early menarche
- ☐ Late first pregnancy (after age 28 years)
- ☐ Nulliparity
- ☐ Late menopause
- ☐ All

/ Breast Imaging

CHAPTER OUTLINE:

Breast Anatomy
Anatomical Variants
Pregnancy and Lactation
Diagnostic Imaging Techniques
Disease of the Breast: Benign
Disease of the Breast: Malignant
Axilla
Interventional Procedures
Screening
High Risk Women
Communication
Multidisciplinary Team Meeting
Take-Home Messages
References
Test Your Knowledge

/ Test Your Knowledge

<?> ANSWER

15 Which of these factors is associated with an increased risk of breast cancer?

- ☐ Early menarche
- ☐ Late first pregnancy (after age 28 years)
- ☐ Nulliparity
- ☐ Late menopause
- ☒ All

/ Breast Imaging

CHAPTER OUTLINE:

Breast Anatomy
Anatomical Variants
Pregnancy and Lactation
Diagnostic Imaging Techniques
Disease of the Breast: Benign
Disease of the Breast: Malignant
Axilla
Interventional Procedures
Screening
High Risk Women
Communication
Multidisciplinary Team Meeting
Take-Home Messages
References
Test Your Knowledge

/ Authors

EDITORS

Federica Pediconi [1]

Fiona J. Gilbert [2]

ASSISTANT EDITOR

Francesca Galati [1]

AFFILIATION

Chairperson of Educational Committee of EUSOBI

[1] Department of Radiological, Oncological and Pathological Sciences, Sapienza University of Rome, Italy

Past President of EUSOBI

[2] Head of Department, Radiology Department, University of Cambridge, Cambridge, UK

<↑> HYPERLINK

federica.pediconi@uniroma1.it

fjg28@medschl.cam.ac.uk

francesca.galati@uniroma1.it

/ Breast Imaging

CHAPTER OUTLINE:

Breast Anatomy

Anatomical Variants

Pregnancy and Lactation

Diagnostic Imaging
Techniques

Disease of the Breast:
Benign

Disease of the Breast:
Malignant

Axilla

Interventional Procedures

Screening

High Risk Women

Communication

Multidisciplinary Team
Meeting

Take-Home Messages

References

Test Your Knowledge

/ Authors

Anatomy

AUTHORS

Simone Schiaffino [1]
Mirjam Wielema [2]

AFFILIATION

[1] Centro di Senologia della Svizzera Italiana Istituto di Imaging della Svizzera Italiana (IIMSI), Lugano, Switzerland
[2] University of Groningen (RUG), Groningen, The Netherlands

Anatomical Variants

AUTHORS

Elisabetta Giannotti [1]
Maria Adele Marino [2]

AFFILIATION

[1] Cambridge University Hospital Trust, Cambridge, UK
[2] Department of Biomedical Sciences and Morphologic and Functional Imaging, University of Messina, Messina, Italy

Pregnancy and Lactation

AUTHORS

Elisabetta Giannotti [1]
Maria Adele Marino [2]

AFFILIATION

[1] Cambridge University Hospital Trust, Cambridge, UK
[2] Department of Biomedical Sciences and Morphologic and Functional Imaging, University of Messina, Messina, Italy

<↑> **HYPERLINK**

ytteb84@hotmail.com
marmarino@unime.it

/ Breast Imaging

CHAPTER OUTLINE:

Breast Anatomy
Anatomical Variants
Pregnancy and Lactation
Diagnostic Imaging Techniques
Disease of the Breast: Benign
Disease of the Breast: Malignant
Axilla
Interventional Procedures
Screening
High Risk Women
Communication
Multidisciplinary Team Meeting
Take-Home Messages
References
Test Your Knowledge

/ Authors

Diagnostic Imaging Techniques

AUTHORS

Filipe Barros Alves [1]

Melis Baykara Ulasan [2]

Francesca Ferrara [3]

Pascal A.T. Baltzer [4]

Paola Clauser [4]

AFFILIATION

[1] Centro Hospitalar Universitário de S. João, EPE and Faculdade de Medicina da Universidade: do Porto, Porto, Portugal;

[2] Istanbul Training and Research Hospital, Istanbul, Turkey;

[3] Dipartimento di Diagnostica per Immagini, Radioterapia Oncologica ed Ematologia, Fondazione Policlinico Universitario "A. Gemelli", IRCCS, Rome, Italy;

[4] Department of Biomedical Imaging and Image-guided Therapy; Medical University of Vienna, Vienna, Austria

/ Breast Imaging

CHAPTER OUTLINE:

Breast Anatomy

Anatomical Variants

Pregnancy and Lactation

Diagnostic Imaging Techniques

Disease of the Breast: Benign

Disease of the Breast: Malignant

Axilla

Interventional Procedures

Screening

High Risk Women

Communication

Multidisciplinary Team Meeting

Take-Home Messages

References

Test Your Knowledge

<↑> HYPERLINK

clauser.p@hotmail.it
patbaltzer@gmail.com

/ Authors

Disease of the Breast: Benign

AUTHORS

Melis Baykara Ulsan [1]

Filipe Barros Alves [2]

Francesca Ferrara [3]

Pascal A.T. Baltzer [4]

Paola Clauser [4]

AFFILIATION

[1] Istanbul Training and Research Hospital, Istanbul, Turkey;

[2] Centro Hospitalar Universitário de S. João, EPE and Faculdade de Medicina da Universidade: do Porto, Porto, Portugal;

[3] Dipartimento di Diagnostica per Immagini, Radioterapia Oncologica ed Ematologia, Fondazione Policlinico Universitario "A. Gemelli", IRCCS, Rome, Italy;

[4] Department of Biomedical Imaging and Image-guided Therapy; Medical University of Vienna, Vienna, Austria

/ Breast Imaging

CHAPTER OUTLINE:

Breast Anatomy

Anatomical Variants

Pregnancy and Lactation

Diagnostic Imaging Techniques

Disease of the Breast: Benign

Disease of the Breast: Malignant

Axilla

Interventional Procedures

Screening

High Risk Women

Communication

Multidisciplinary Team Meeting

Take-Home Messages

References

Test Your Knowledge

<↑> HYPERLINK

clauser.p@hotmail.it
patbaltzer@gmail.com

/ Authors

Disease of the Breast: Malignant

AUTHORS

Chantal Van Ongeval [1]

AFFILIATION

[1] UZ Leuven, University Hospitals of Leuven, Faculty of Medicine, University of Leuven, Belgium

Axilla

AUTHORS

Fleur Kilburn-Toppin [1]

Thiemo J.A. van Nijnatten [2]

AFFILIATION

[1] Cambridge Breast Unit, Cambridge University Hospital NHS Foundation Trust, Addenbrookes' Hospital, Hills Road, Cambridge CB2 0QQ, UK

[2] Department of Radiology and Nuclear Medicine, Maastricht University Medical Center+, the Netherlands

<↑> **HYPERLINK**

Chantal.vanongeval@uzleuven.be

fleurkilburntoppin@gmail.com

thiemo.nijnatten@mumc.nl

/ Breast Imaging

CHAPTER OUTLINE:

Breast Anatomy

Anatomical Variants

Pregnancy and Lactation

Diagnostic Imaging Techniques

Disease of the Breast: Benign

Disease of the Breast: Malignant

Axilla

Interventional Procedures

Screening

High Risk Women

Communication

Multidisciplinary Team Meeting

Take-Home Messages

References

Test Your Knowledge

/ Authors

Interventional Procedures

AUTHORS

Rubina Manuela Trimboli [1]

Giulia Vatteroni [2]

AFFILIATION

[1] IRCCS Humanitas Research Hospital, Via
Manzoni 56, 20089 Rozzano, Milan, Italy

[2] Department of Biomedical Sciences,
Humanitas University, Via Rita Levi Mon-
talcini 4, Pieve Emanuele, Milan, Italy

Screening

AUTHORS

Jessica Muscat [1]

AFFILIATION

[1] Medical Imaging Department, Mater
Dei Hospital, Msida, Malta

<↑> HYPERLINK

trimboli.rm@gmail.com

giulia.vatteroni@gmail.com

jessica.muscat@gov.mt

/ Breast Imaging

CHAPTER OUTLINE:

Breast Anatomy

Anatomical Variants

Pregnancy and Lactation

Diagnostic Imaging
Techniques

Disease of the Breast:
Benign

Disease of the Breast:
Malignant

Axilla

Interventional Procedures

Screening

High Risk Women

Communication

Multidisciplinary Team
Meeting

Take-Home Messages

References

Test Your Knowledge

/ Authors

High Risk Women

AUTHORS

Elisabetta Giannotti [1]

Maria Adele Marino [2]

AFFILIATION

[1] Cambridge University Hospital Trust, Cambridge, UK

[2] Department of Biomedical Sciences and Morphologic and Functional Imaging, University of Messina, Messina, Italy

Communication

AUTHORS

Jessica Muscat [1]

Francesca Galati [2]

AFFILIATION

[1] Medical Imaging Department, Mater Dei Hospital, Msida, Malta

[2] Department of Radiological, Oncological and Pathological Sciences, Sapienza University of Rome, Italy

<↑> **HYPERLINK**

ytteb84@Hotmail.com

marmarino@unime.it

jessica.muscat@gov.mt

francesca.galati@uniroma1.it

/ Breast Imaging

CHAPTER OUTLINE:

Breast Anatomy

Anatomical Variants

Pregnancy and Lactation

Diagnostic Imaging Techniques

Disease of the Breast: Benign

Disease of the Breast: Malignant

Axilla

Interventional Procedures

Screening

High Risk Women

Communication

Multidisciplinary Team Meeting

Take-Home Messages

References

Test Your Knowledge

/ Authors

Multidisciplinary Team Meeting

AUTHORS

Fleur Kilburn-Toppin [1]

Thiemo J.A. van Nijnatten [2]

Francesca Galati [3]

AFFILIATION

[1] Cambridge Breast Unit, Cambridge University Hospital NHS Foundation Trust, Addenbrookes' Hospital, Hills Road, Cambridge CB2 0QQ, UK

[2] Department of Radiology and Nuclear Medicine, Maastricht University Medical Center+, the Netherlands

[3] Department of Radiological, Oncological and Pathological Sciences, Sapienza University of Rome, Italy

<↑> HYPERLINK

fleurkilburntoppin@gmail.com

thiemo.nijnatten@mumc.nl

francesca.galati@uniroma1.it

/ Breast Imaging

CHAPTER OUTLINE:

Breast Anatomy

Anatomical Variants

Pregnancy and Lactation

Diagnostic Imaging
Techniques

Disease of the Breast:
Benign

Disease of the Breast:
Malignant

Axilla

Interventional Procedures

Screening

High Risk Women

Communication

Multidisciplinary Team
Meeting

Take-Home Messages

References

Test Your Knowledge

/ Authors

Take-Home Messages

AUTHORS

Federica Pediconi [1]

Fiona J. Gilbert [2]

AFFILIATION

[1] Department of Radiological, Oncological and Pathological Sciences, Sapienza University of Rome, Italy

[2] Head of Department, Radiology Department, University of Cambridge, Cambridge, UK

<↑> HYPERLINK

federica.pediconi@uniroma1.it

fjg28@medschl.cam.ac.uk

/ Breast Imaging

CHAPTER OUTLINE:

Breast Anatomy

Anatomical Variants

Pregnancy and Lactation

Diagnostic Imaging
Techniques

Disease of the Breast:
Benign

Disease of the Breast:
Malignant

Axilla

Interventional Procedures

Screening

High Risk Women

Communication

Multidisciplinary Team
Meeting

Take-Home Messages

References

Test Your Knowledge

/ Authors

Test Your Knowledge

AUTHORS

Mirjam Wielema [1]

Federica Pediconi [2]

Francesca Galati [2]

AFFILIATION

[1] University Medical Center Groningen and Elisabeth TweeSteden Hospital, The Netherlands

[2] Department of Radiological, Oncological and Pathological Sciences, Sapienza University of Rome, Italy

<↑> HYPERLINK

mirjamwielema@hotmail.com

federica.pediconi@uniroma1.it

francesca.galati@uniroma1.it

/ Breast Imaging

CHAPTER OUTLINE:

Breast Anatomy

Anatomical Variants

Pregnancy and Lactation

Diagnostic Imaging
Techniques

Disease of the Breast:
Benign

Disease of the Breast:
Malignant

Axilla

Interventional Procedures

Screening

High Risk Women

Communication

Multidisciplinary Team
Meeting

Take-Home Messages

References

Test Your Knowledge

